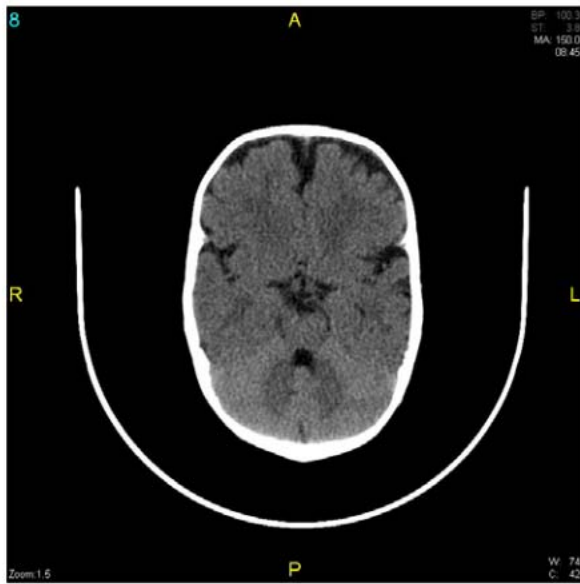


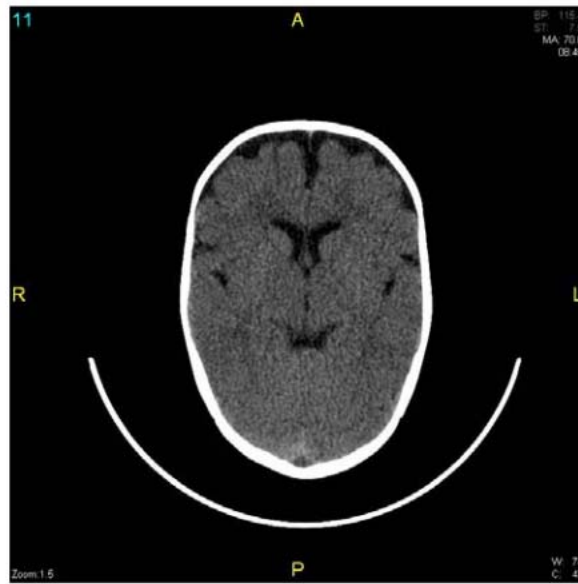
Interesting Cases

Case #0001 - Infant with MACROCEPHALY

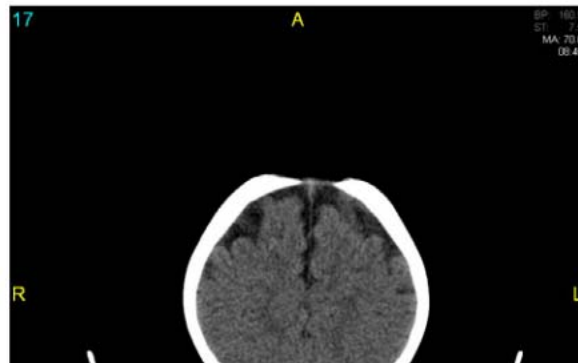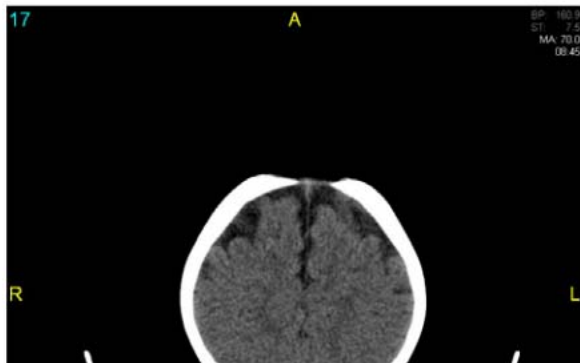History: None given.



CT - 1



CT - 2



Answer: It's OK to call this study normal. Try not to use the term external hydrocephalus, although it is an accepted term. It just sounds bad to the parents, I guess. If you want to be a purist, describe it as a benign enlargement of subarachnoid space, or something like that. It is self-limiting. Mention, if you want, no mass effect, hematoma, or hydrocephalus ventriculomegaly).

DDX of macrocephaly: Big mom and dad with large heads, true hydrocephalus, mass blocking csf drainage, hematoma, and weird stuff like alexander and canavan.