

# Radiological Identification of Complications Following Bariatric Surgery

Alexander Onopchenko,MD

19 July 2017

# Types of Bariatric Operations

- **Restrictive**
  - Adjustable Gastric Band (AGB)
  - Sleeve Gastrectomy (SG)
  - Vertical Banded Gastroplasty (historical)
- **Malabsorptive**
  - Biliopancreatic diversion with duodenal switch (DS)
  - Single anastomosis duodenal interposition (SADI)
- **Combined**
  - Laparoscopic Roux en Y Gastric Bypass (LRYGB)
  - Open Roux en Y Gastric Bypass (ORYGB)

# Adjustable Gastric Band

## Types of AGB

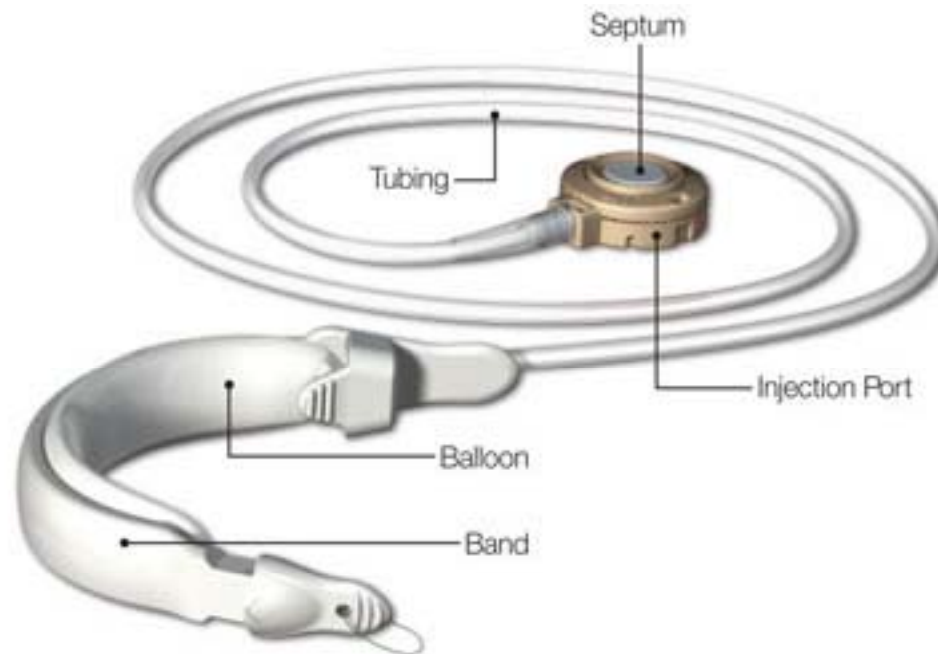
- Lap-Band (Allergan, now Apollo Endosurgery)



# Adjustable Gastric Band

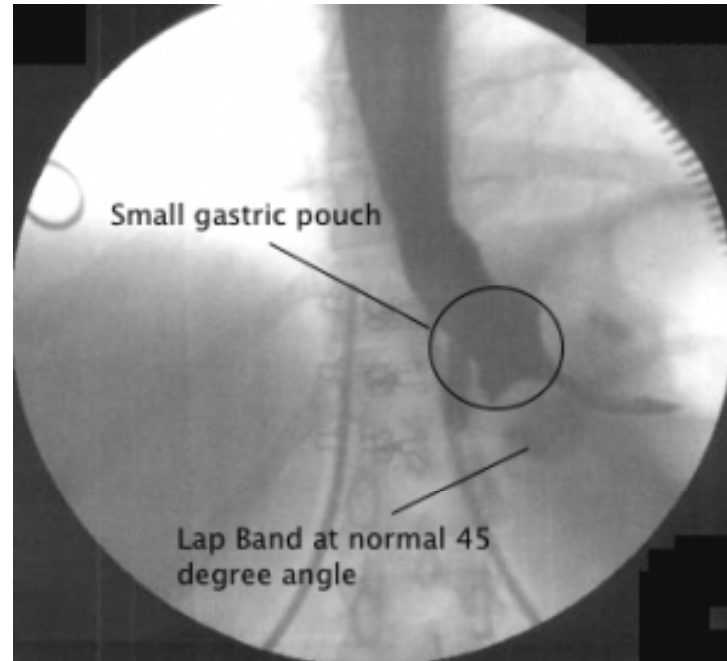
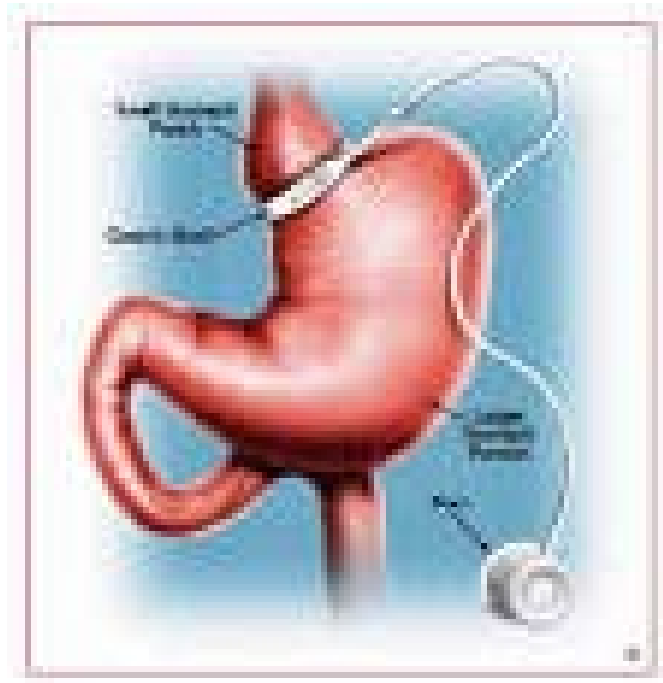
## Types of AGB

- Realize Band (Ethicon- discontinues)



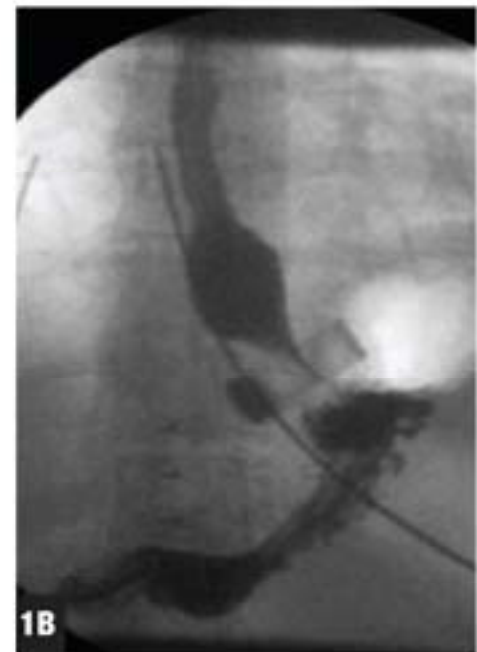
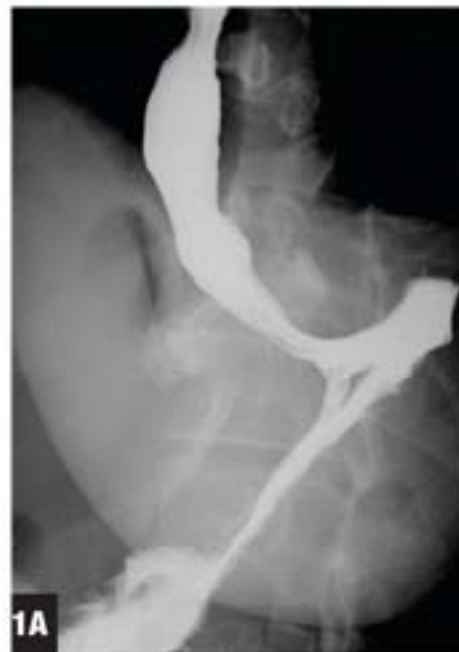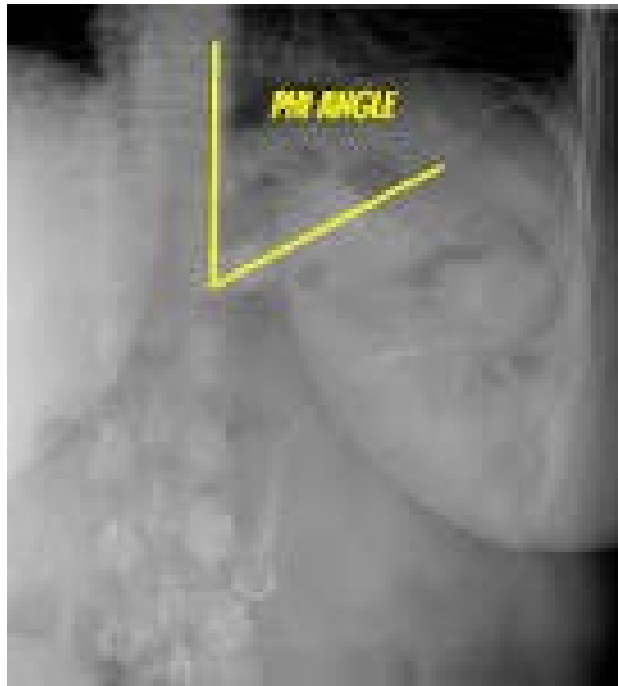
# Adjustable Gastric Band

- Normal Placement



# Adjustable Gastric Band

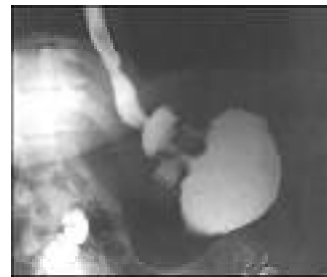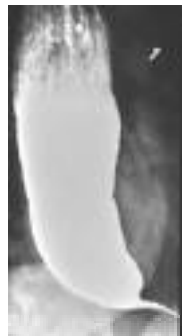- Normal Placement  
Phi Angle Between 4-58 degrees



**FIGURE 1.** Normal postoperative swallow radiographic appearance following LAGB placement (1A); Band adjusted.<sup>20</sup> A small proximal pouch is connected to the stomach through a thin stoma, (1B)

# Adjustable gastric Band

- Complications
    - **Esophageal and our pouch dilitation-** position of band between normal and horizontal
- New onset vomiting, dysphagia GERD (Not acute)



# Adjustable Gastric Band

- Complications

**Slipped Band**- not really downward movement of the band but fundus herniating through and over left side of band

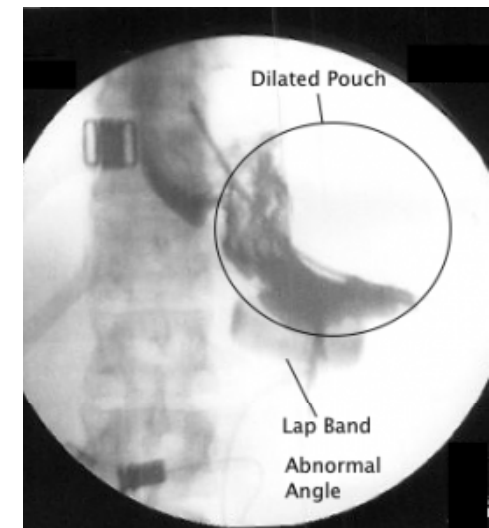
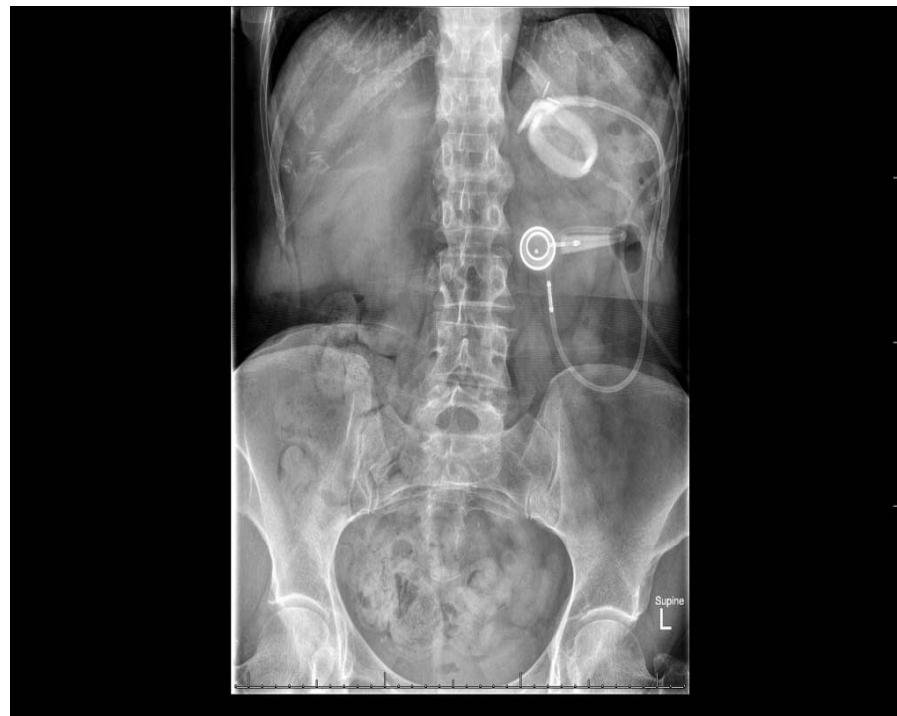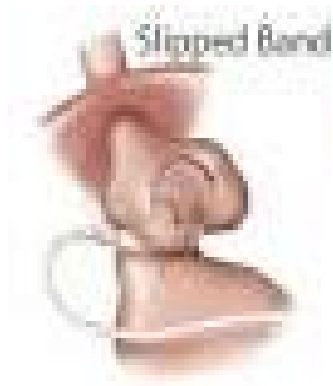
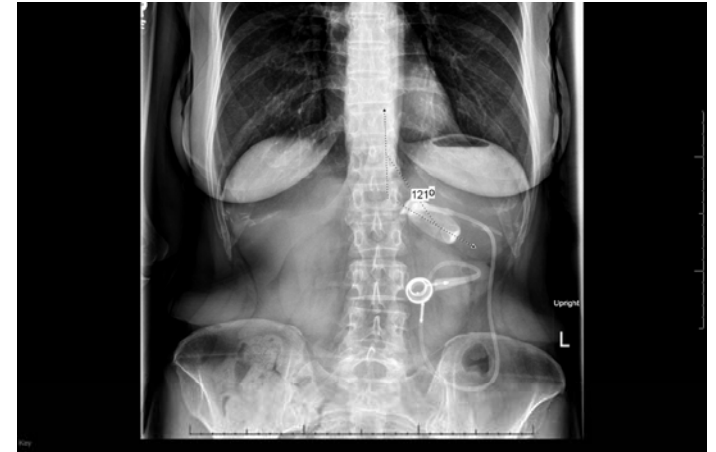- Acute onset (24-48 hours) of progressive dysphagia to complete inability to swallow solids , the liquids with possible

- Angle of the band much greater than horizontal 11-4 instead of 2-8

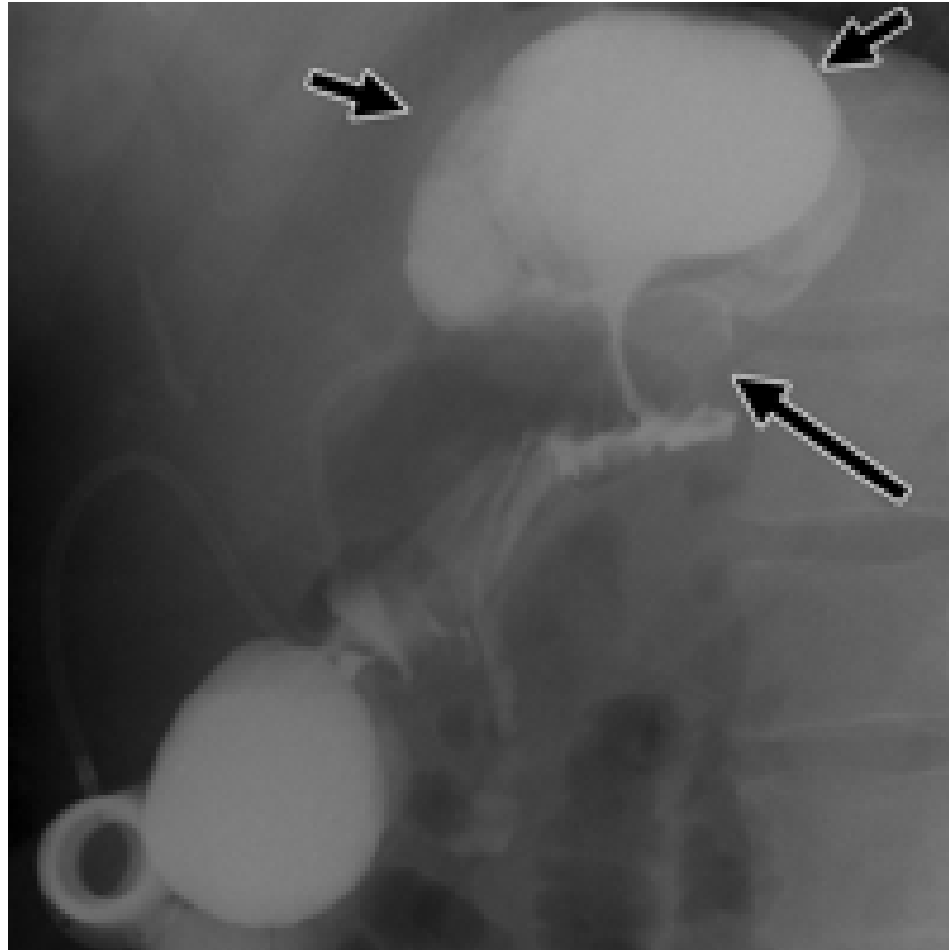


# Adjustable Gastric Band

- Complications
  - Slipped Band**



What is this?



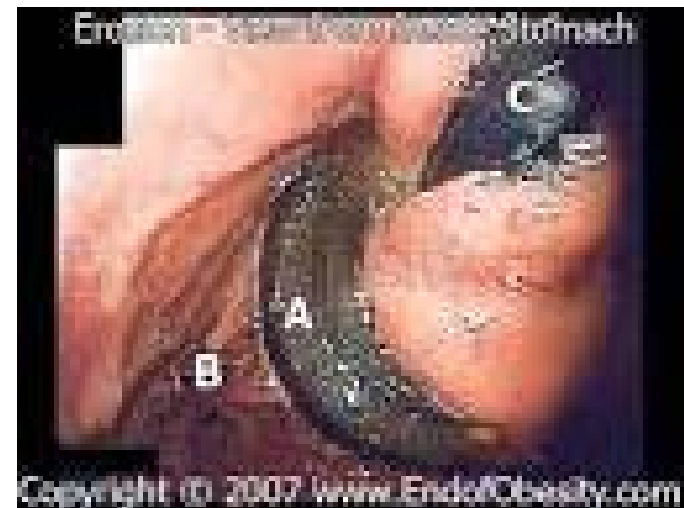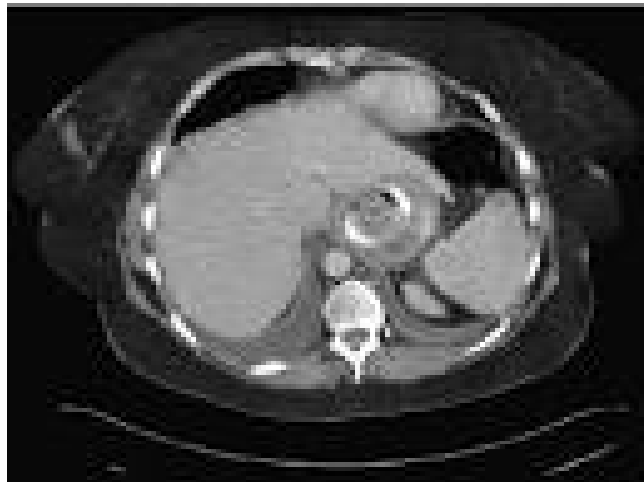
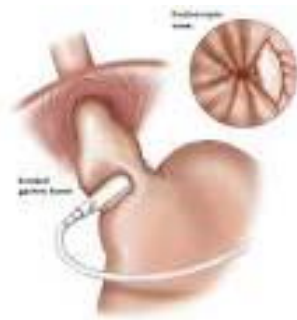# Adjustable Gastric Band

- Complications
  - **Erosion** –symptoms are vague and chronic such as worsening epigastric discomfort, GERD, lack of restriction or distant port site infection. Commonly asymptomatic.

Diagnosis by endoscopy not radiology- maybe subtle finding of air around band or port or phlegmatous changes around band

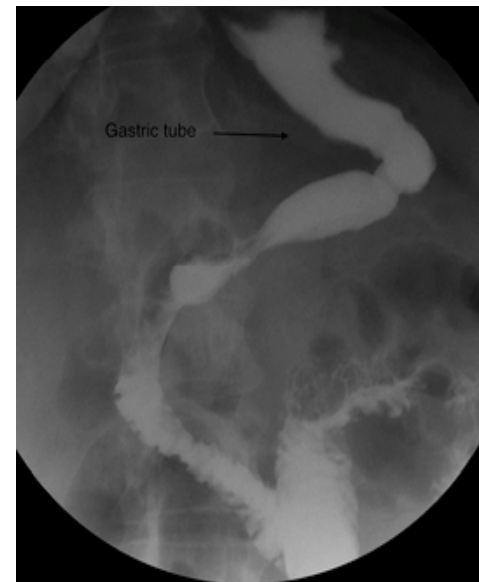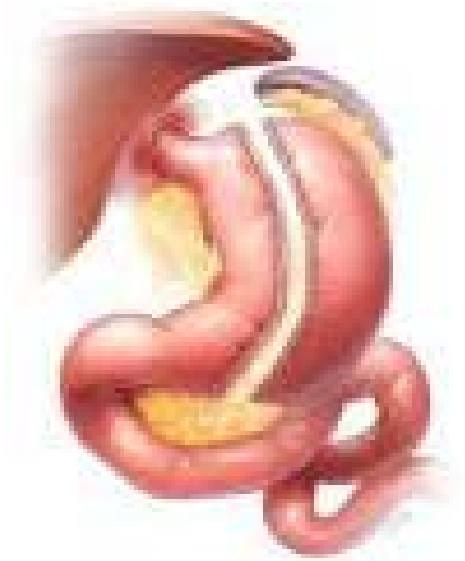# Adjustable Gastric Band

- Complications
  - Erosion



# Sleeve Gastrectomy

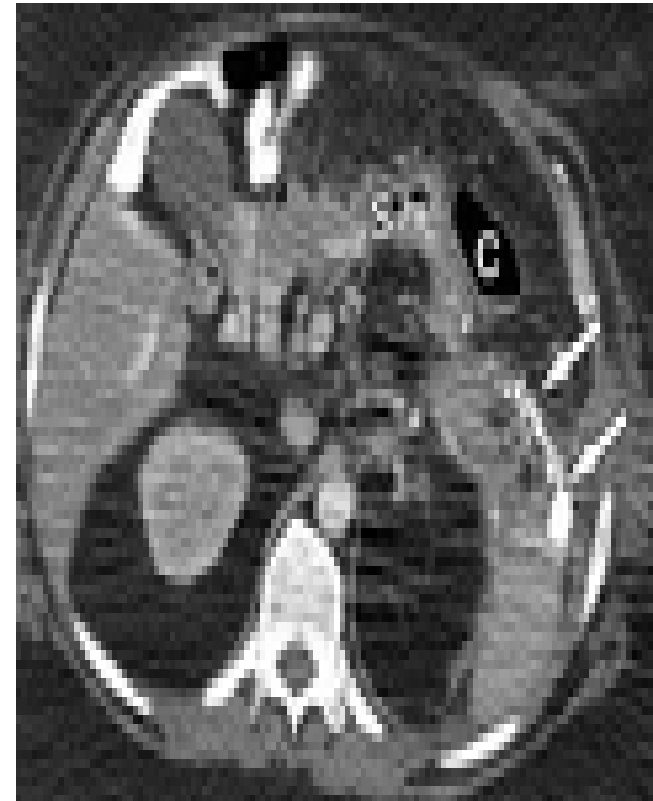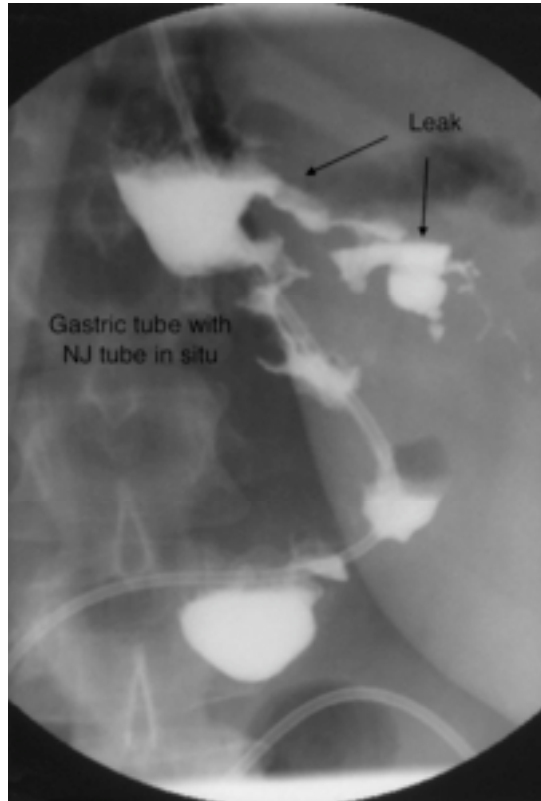
- Normal Anatomy



# Sleeve Gastrectomy

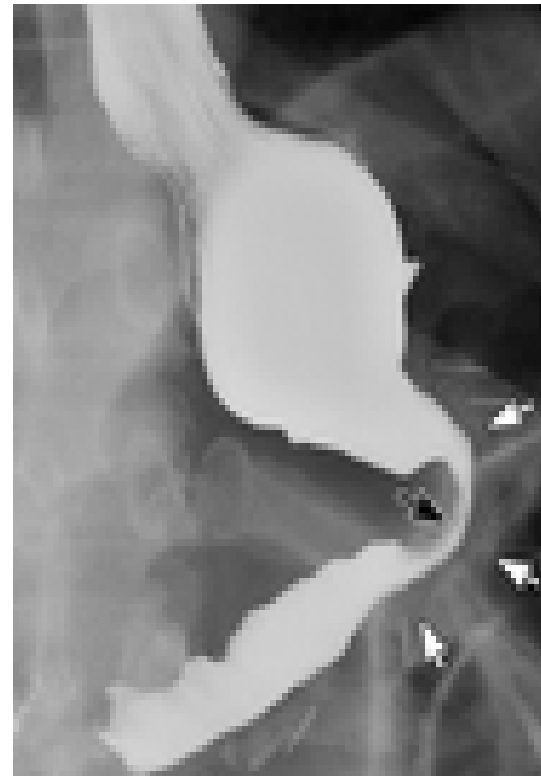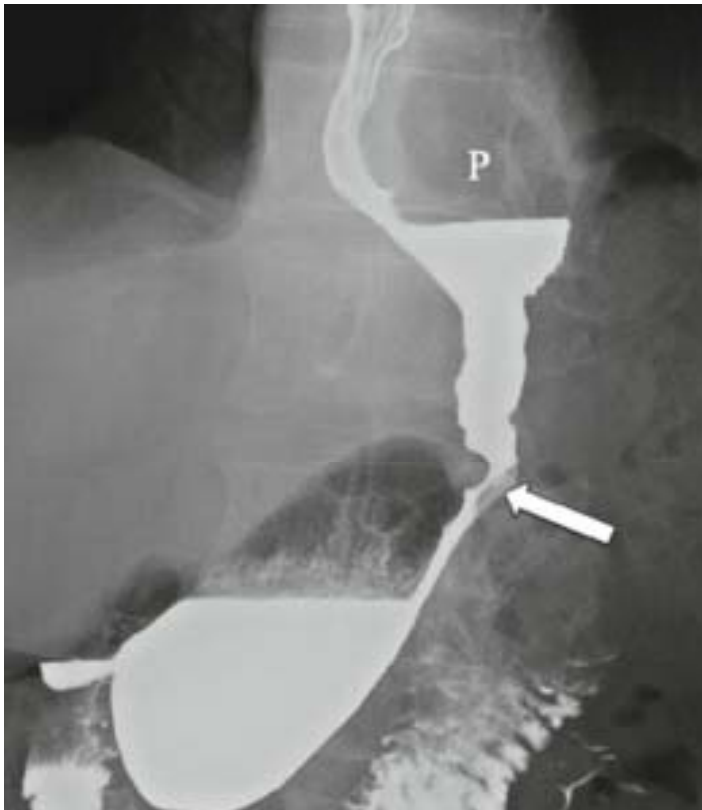- Complications

## -Leak



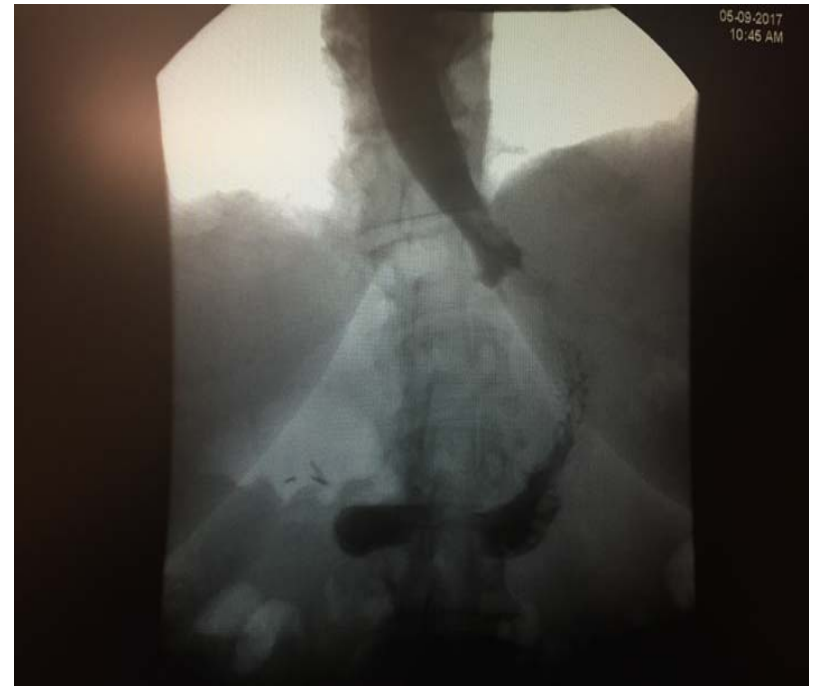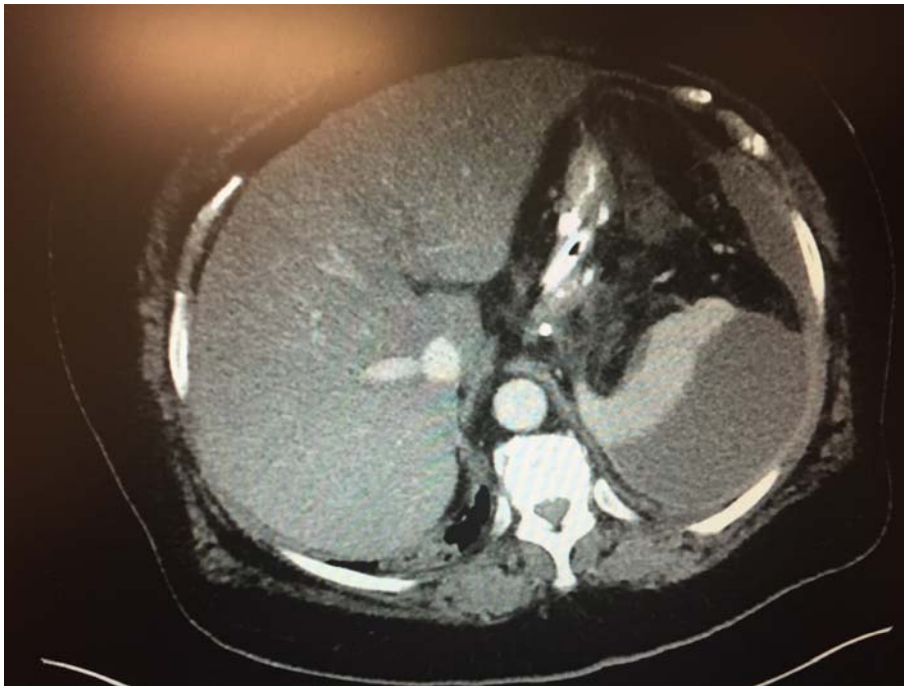
# Sleeve Gastrectomy

- Complications
  - **Stricture**



# Sleeve Gastrectomy

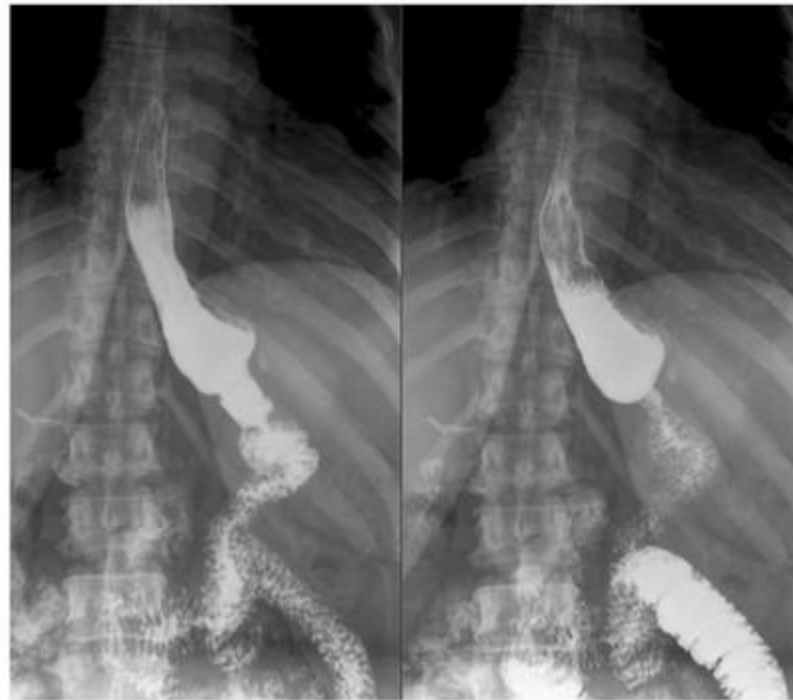
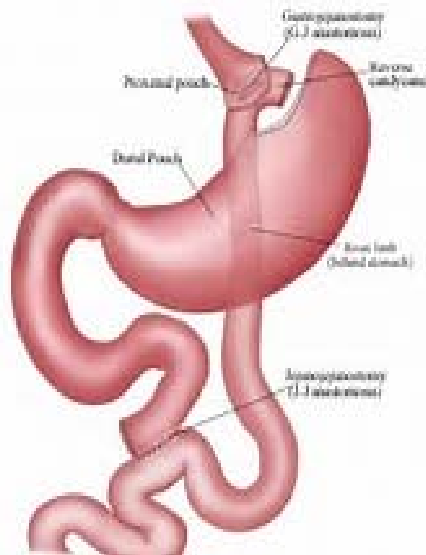
- Complications
  - Intraabdominal abcess





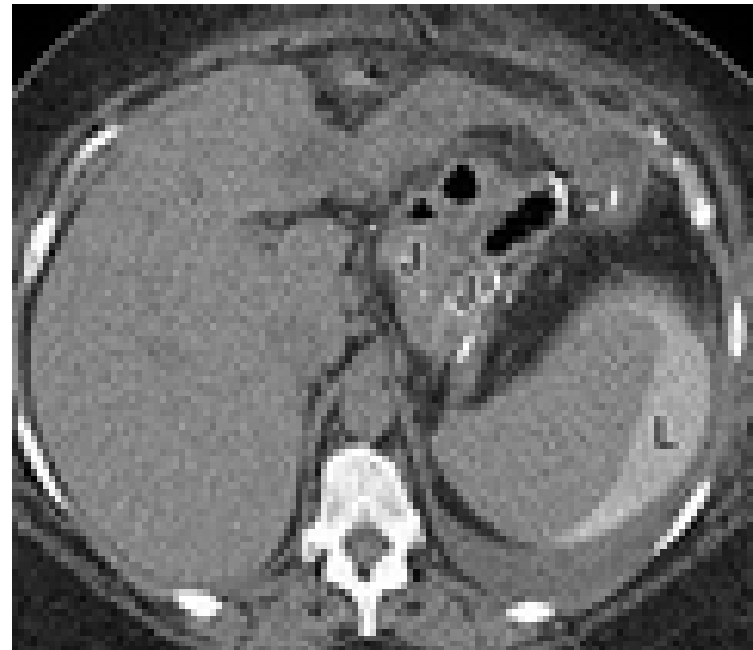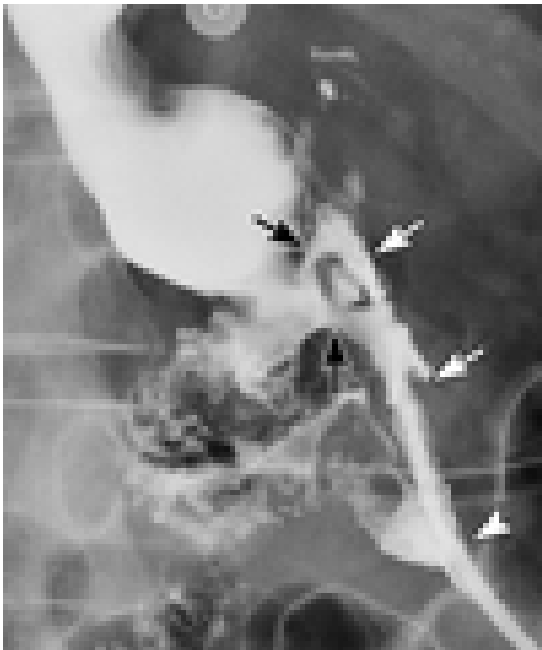# Gastric Bypass

- Normal Anatomy



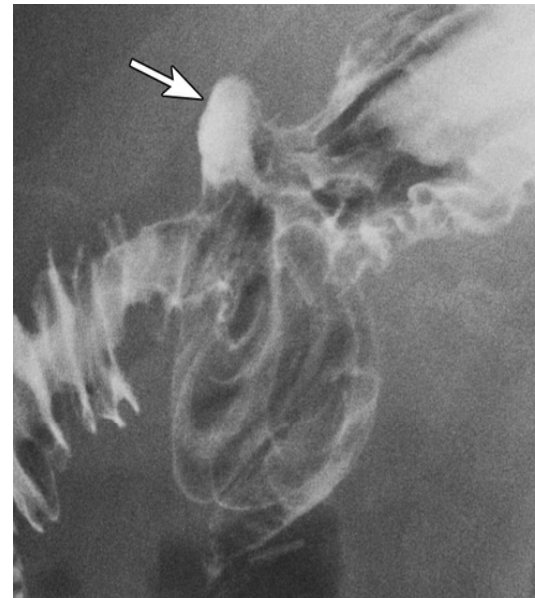
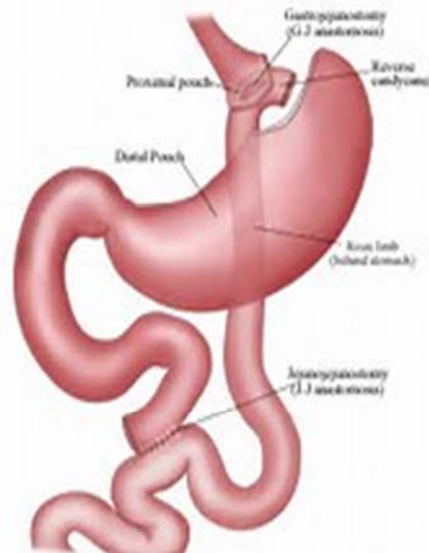
# Gastric Bypass

- Early Complication
  - Leak



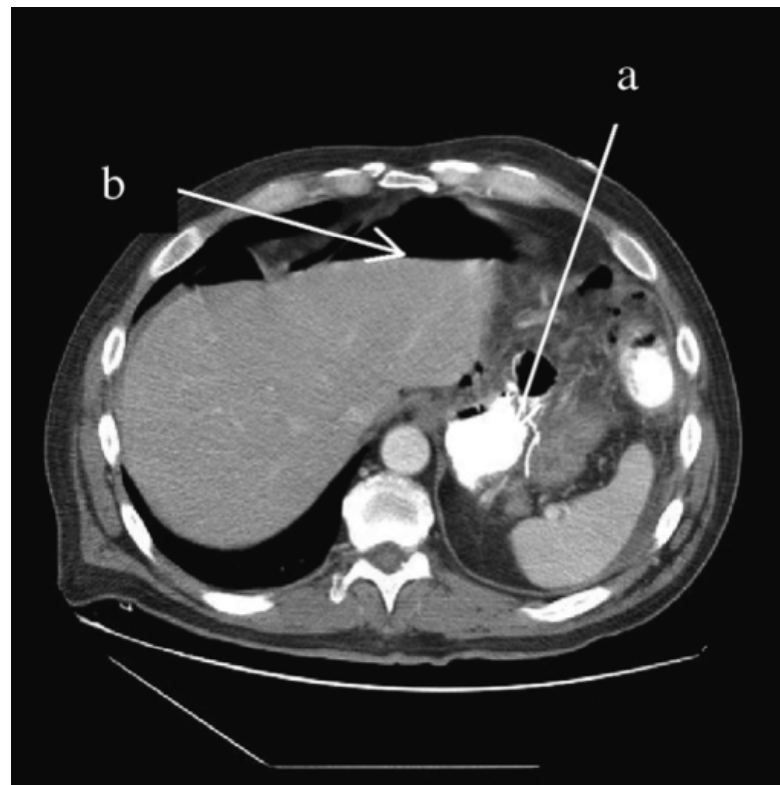
# Gastric Bypass

- Late Complications
  - Marginal ulcer



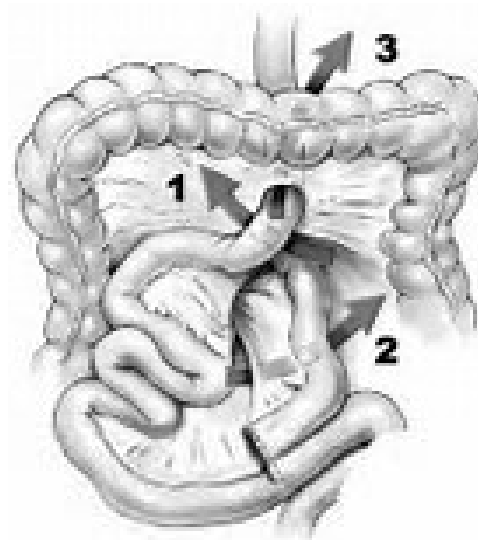
# Gastric Bypass

- Late Complications
  - Perforated marginal ulcer

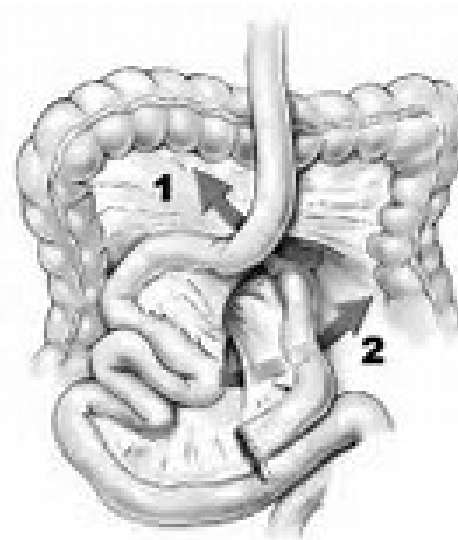


# Gastric Bypass

- Late Complications
  - Internal Hernia

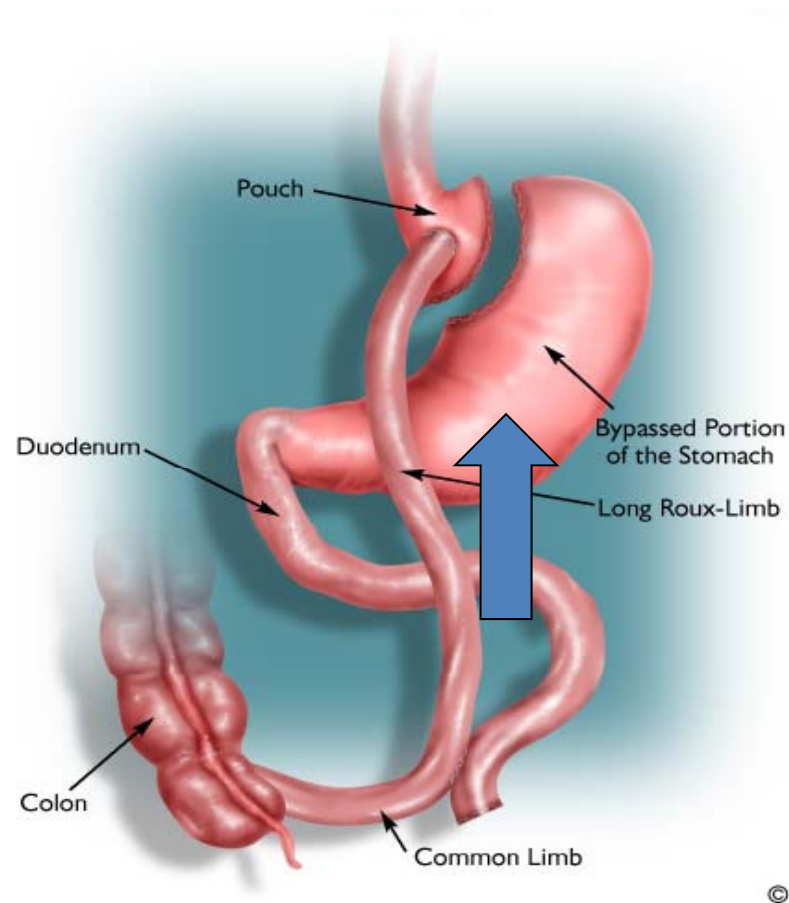


RETROCOLIC

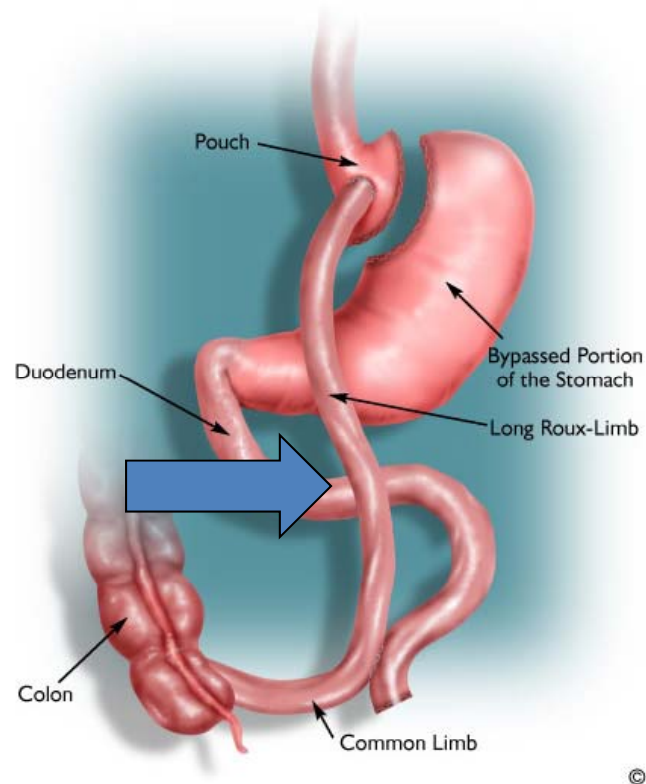


ANTECOLIC

# Type 1 Internal Hernia (through mesocolon)

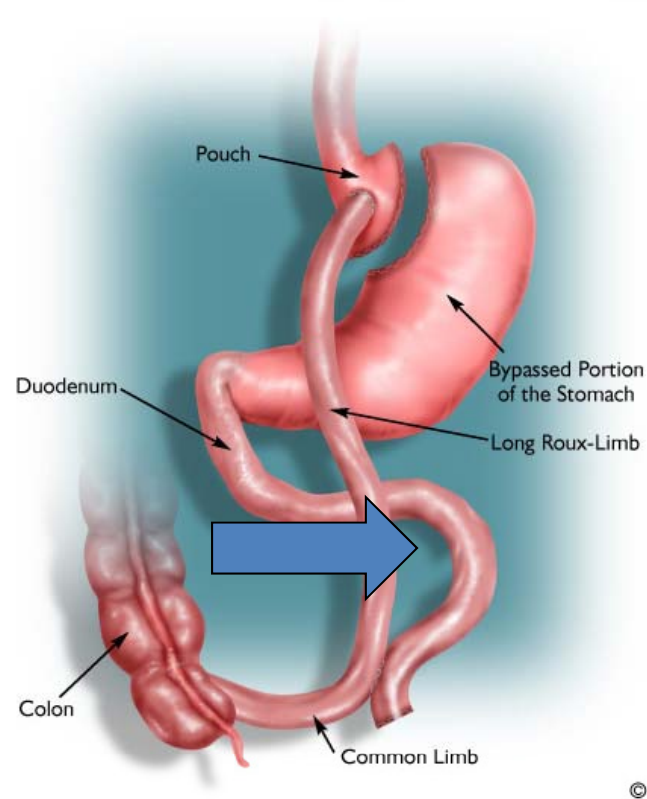


# Type 2 Internal Hernia (Peterson's)

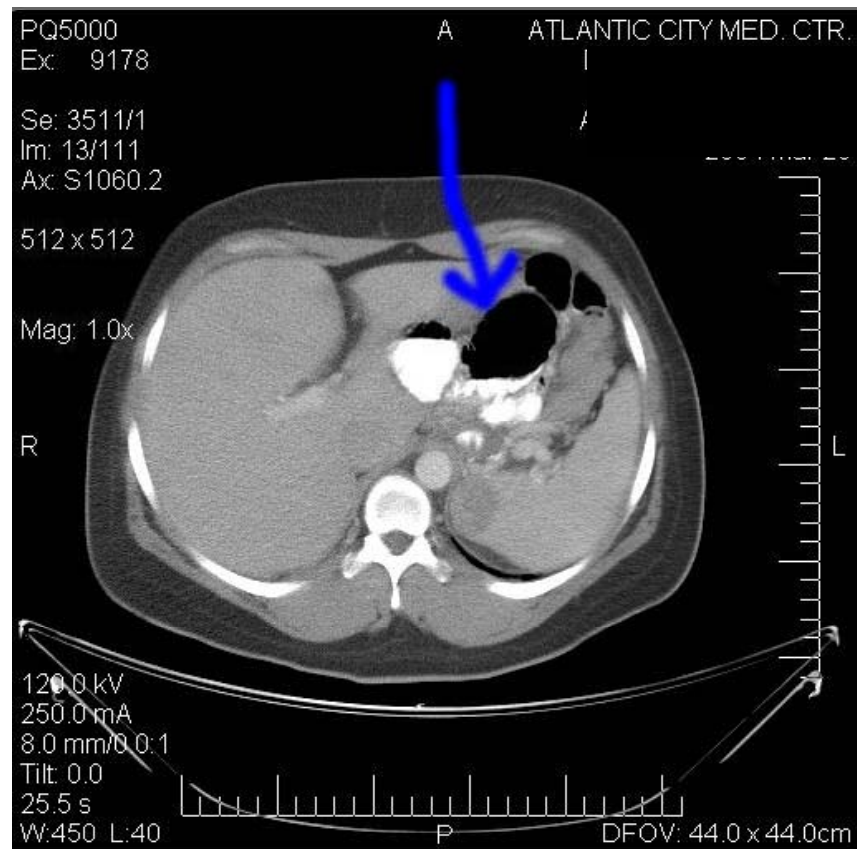
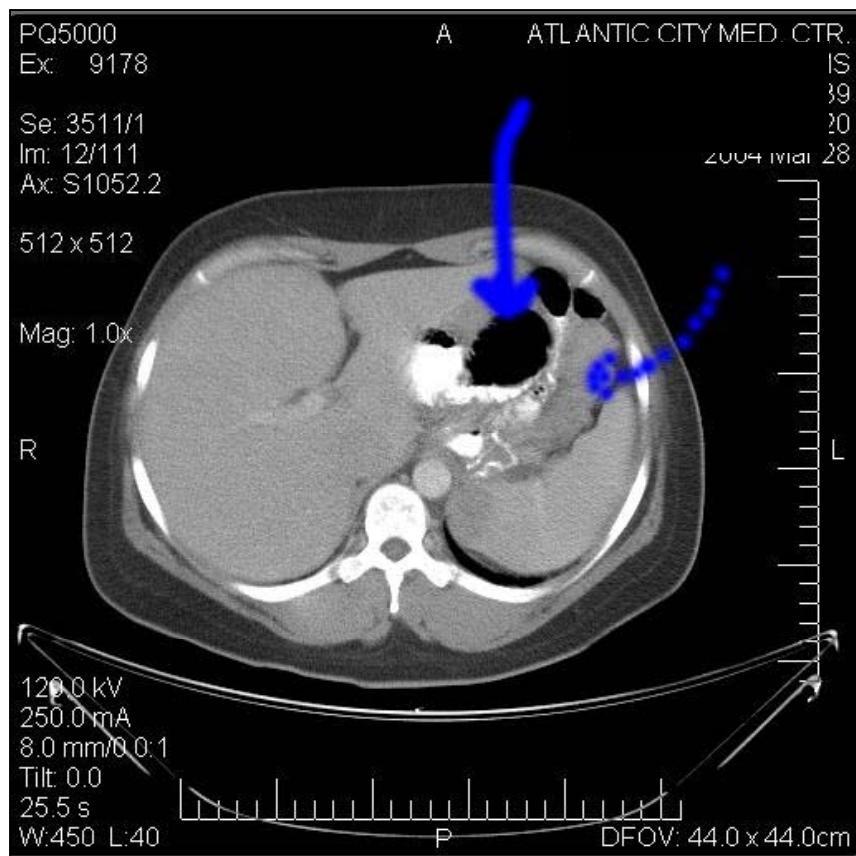


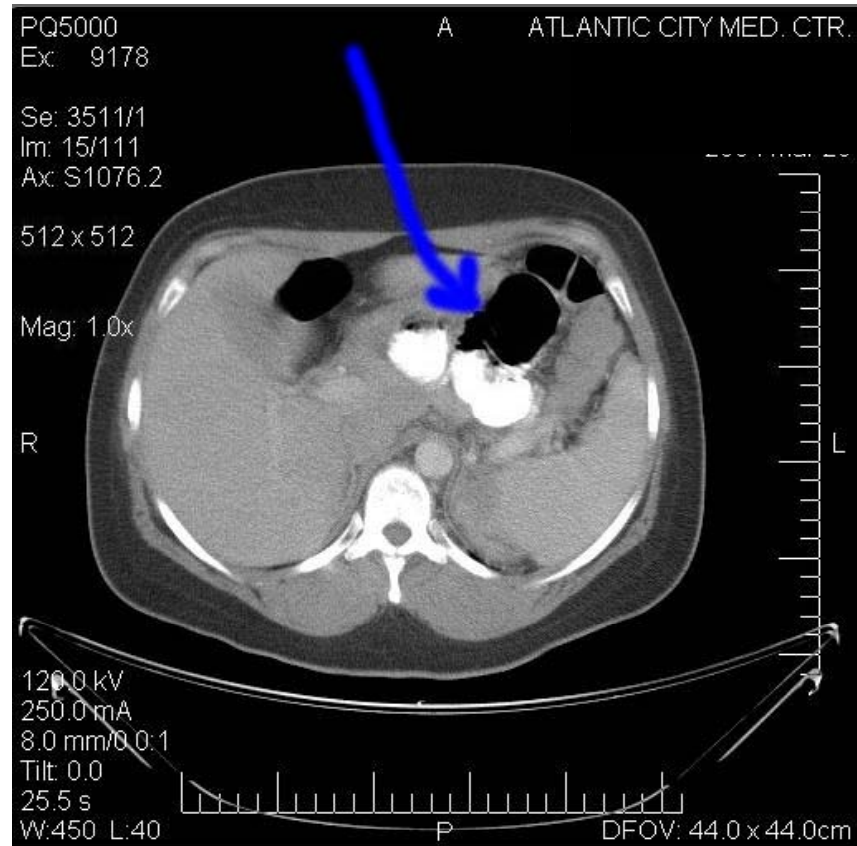
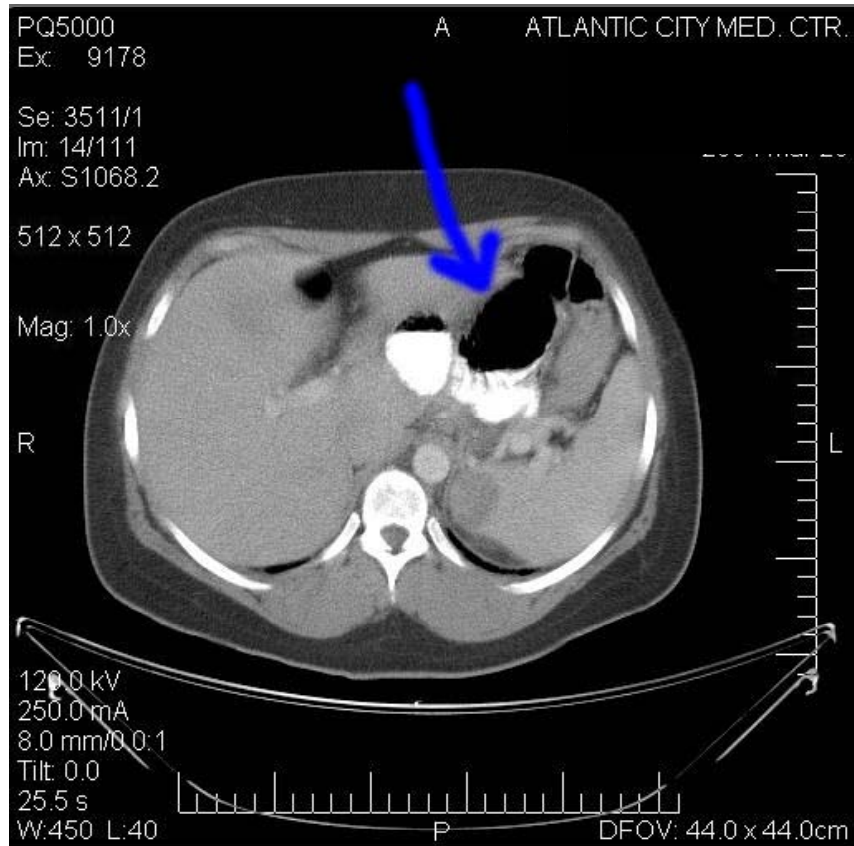
ASBS

# Type 3 Internal Hernia (through defect in small bowel mesentery)









MCWILLIAMS, DAVINE

ATLANTIC CITY MEDICAL CENTER

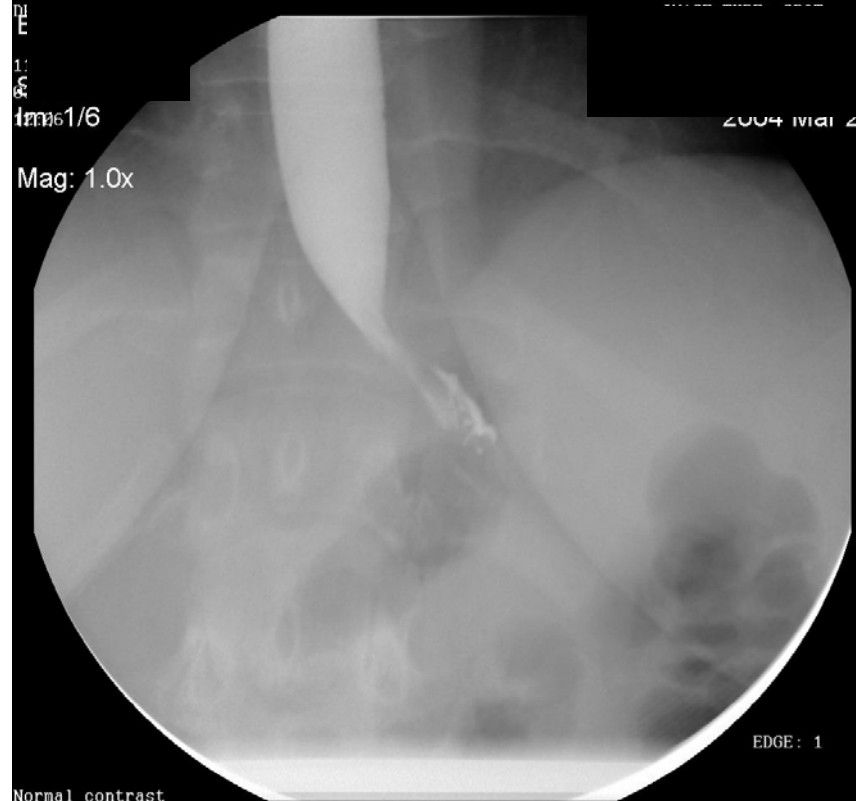
DI  
E

1:  
&

1m61/6

2004 11 11 23

Mag: 1.0x



EDGE: 1

Normal contrast  
W:255 L:127

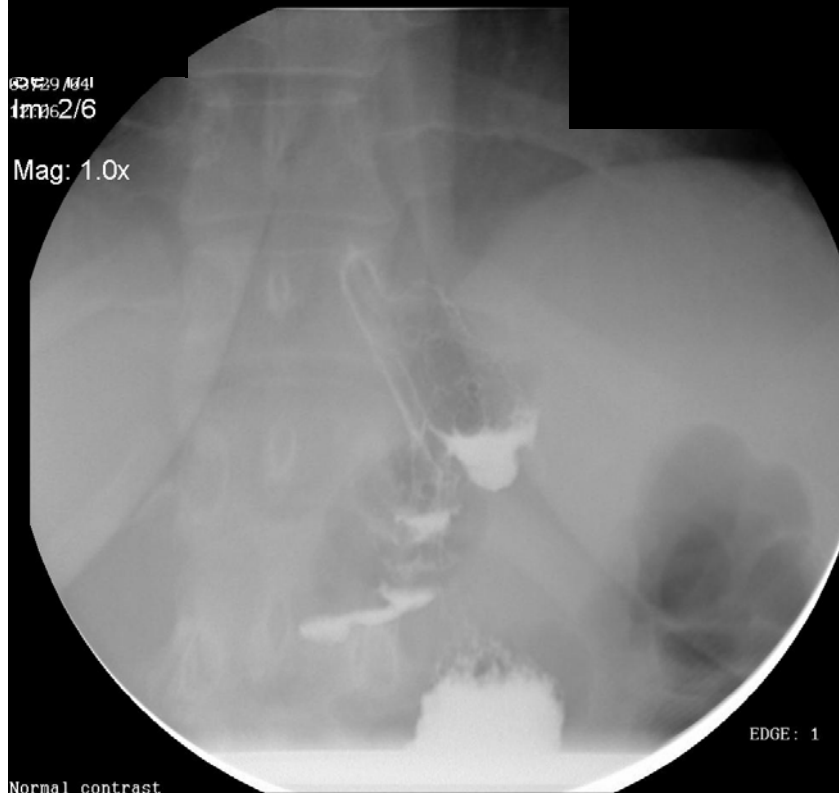ATLANTIC CITY MEDICAL CENTER

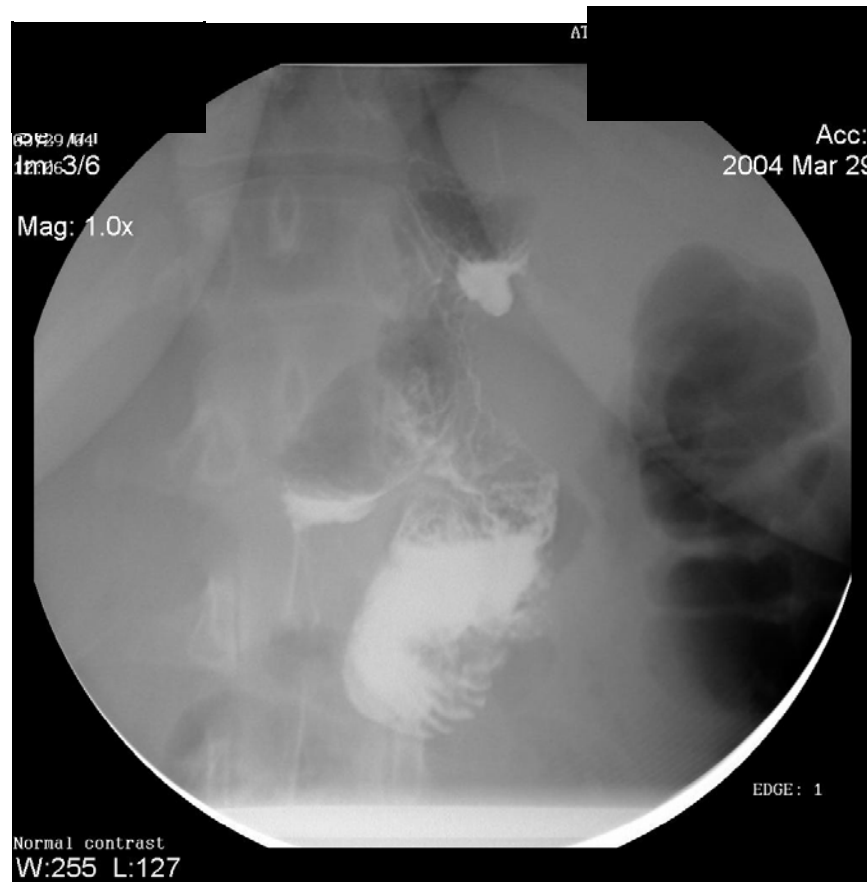
00129 / 041  
Im 062/6

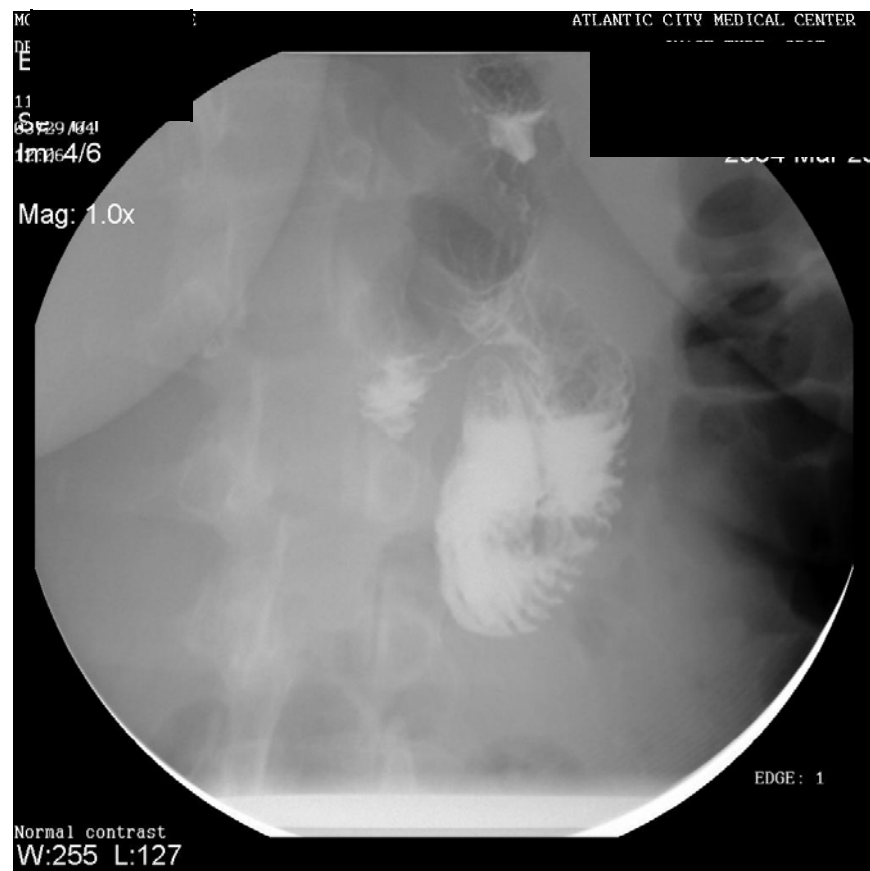Mag: 1.0x

Normal contrast  
W:255 L:127

EDGE: 1







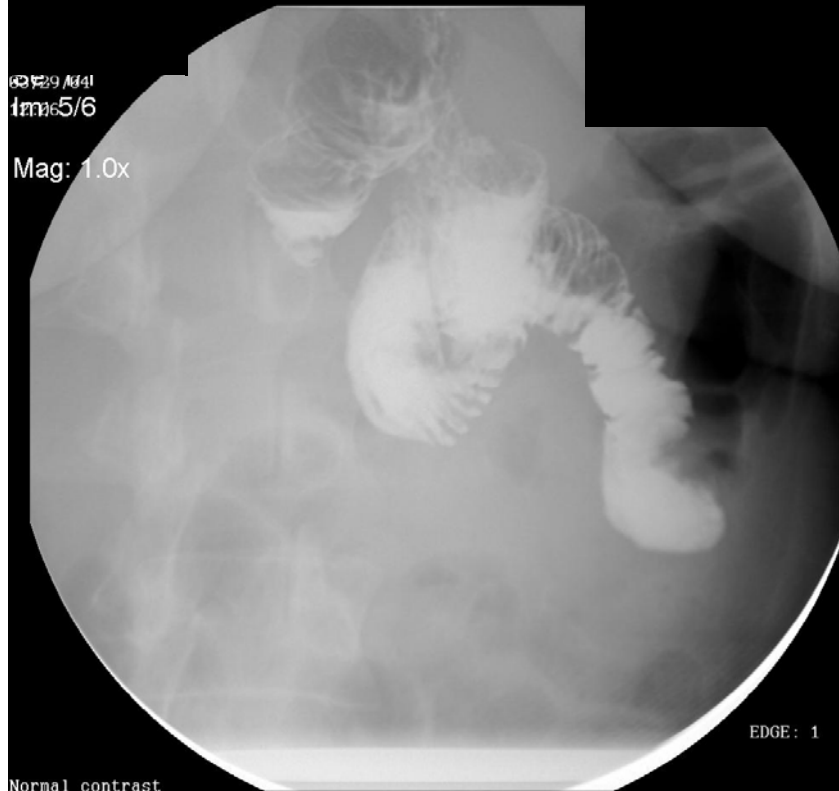ATLANTIC CITY MEDICAL CENTER

00129 1041  
Im 5/6

Mag: 1.0x

Normal contrast  
W:255 L:127

EDGE: 1



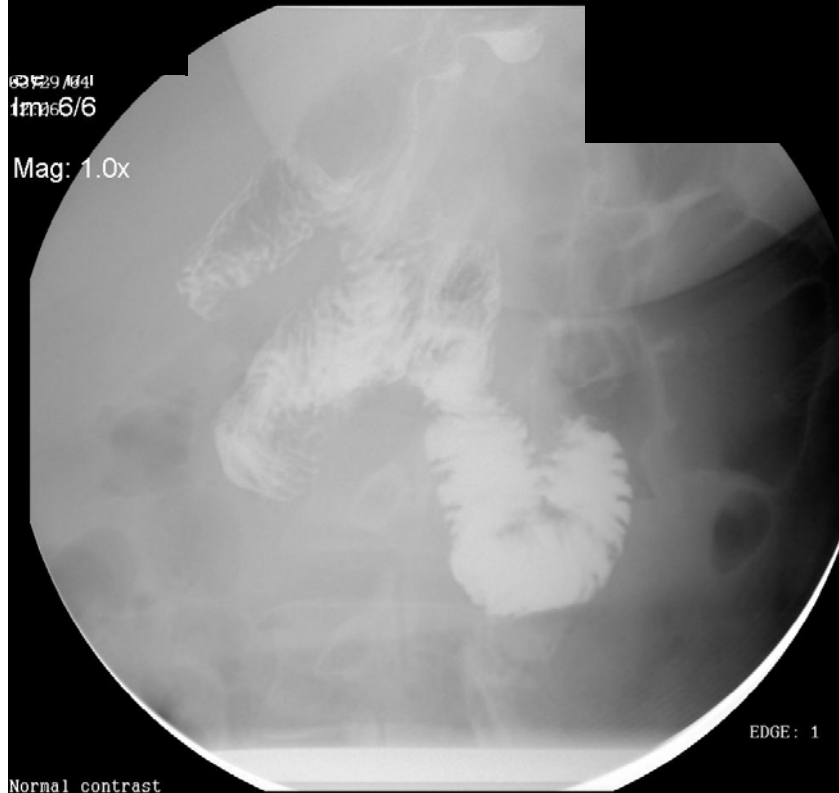ATLANTIC CITY MEDICAL CENTER

00129 1041  
Im 6/6

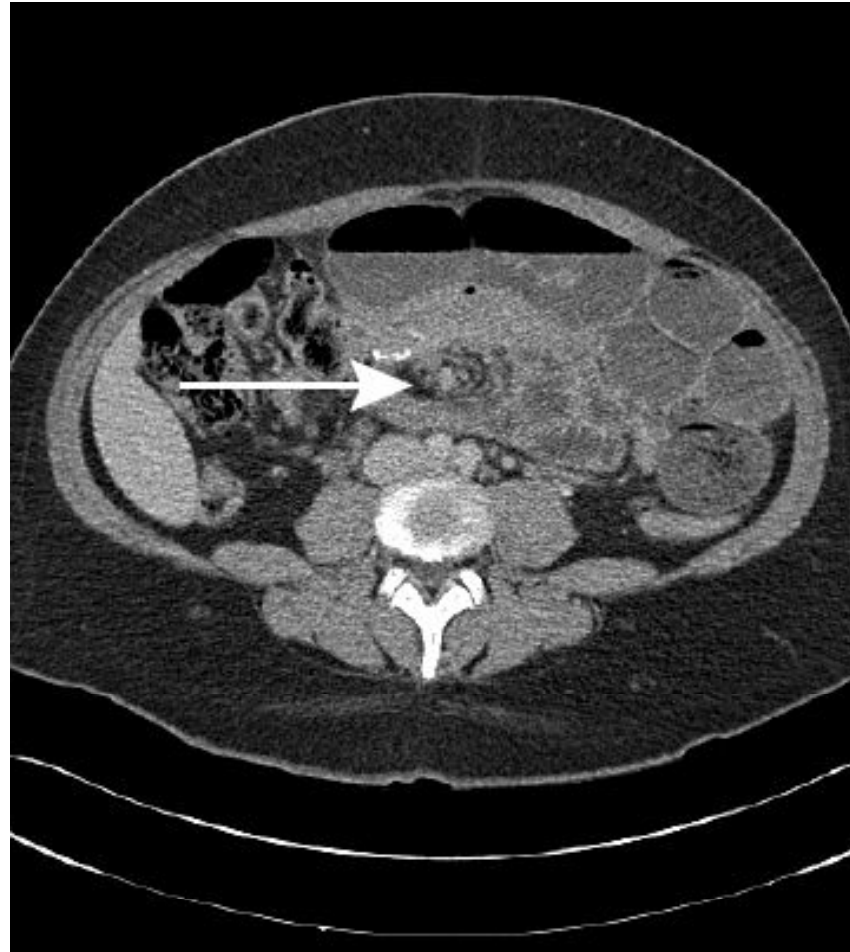Mag: 1.0x

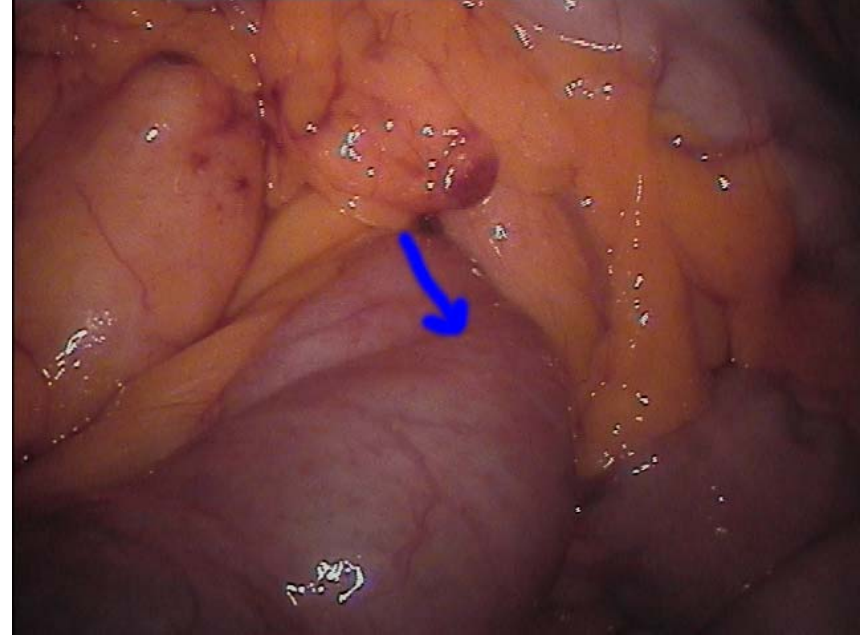
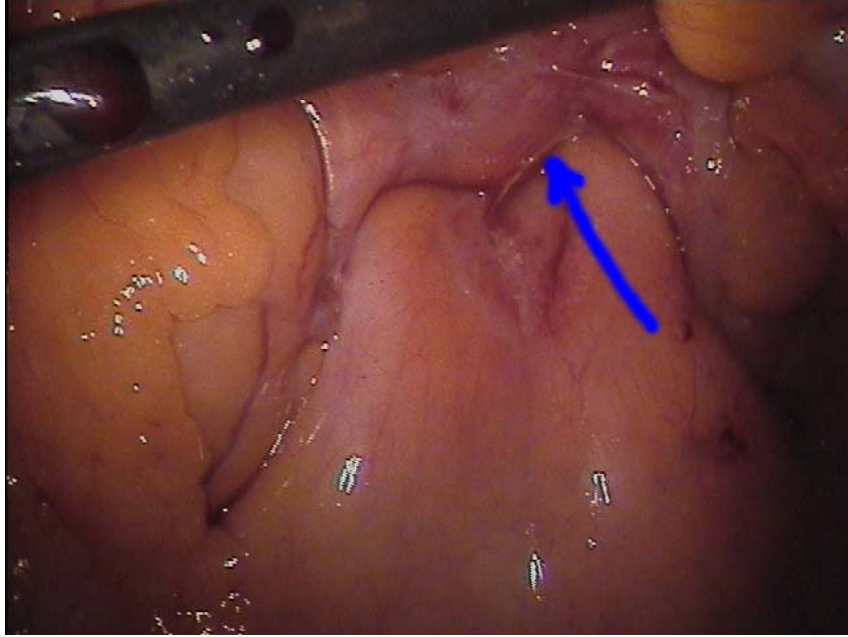
Normal contrast  
W:255 L:127

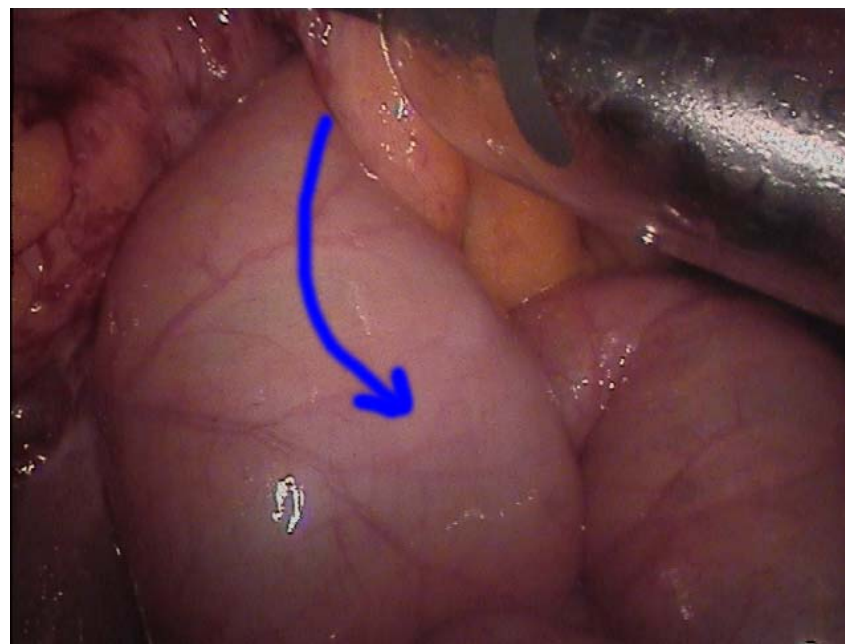
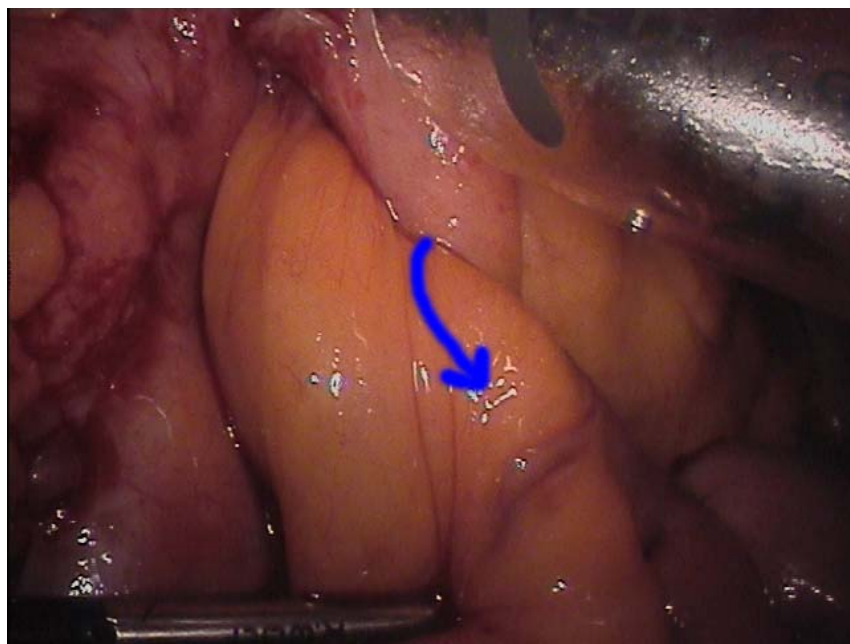
EDGE: 1

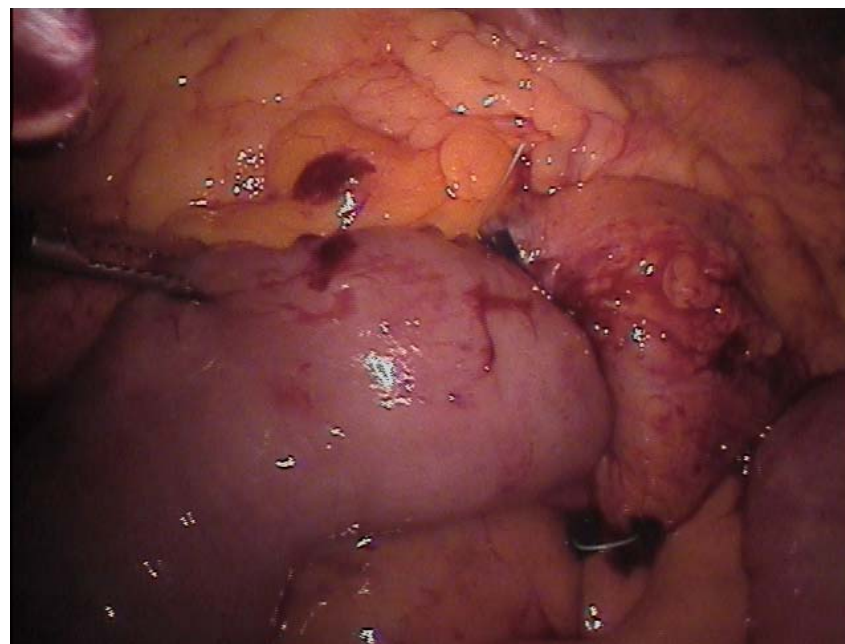
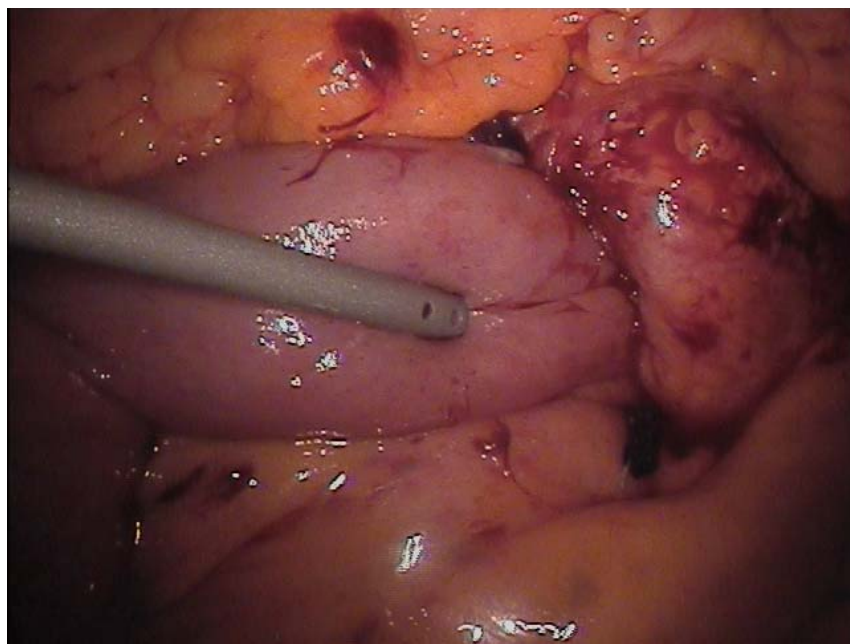






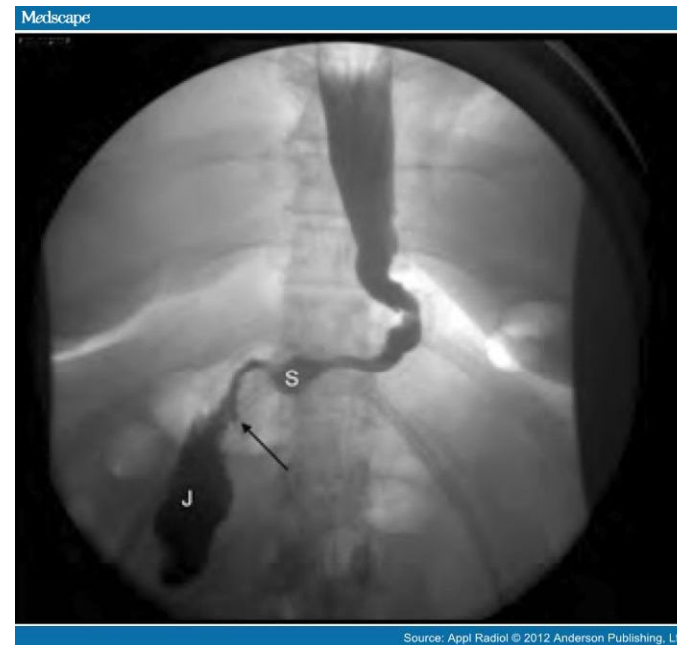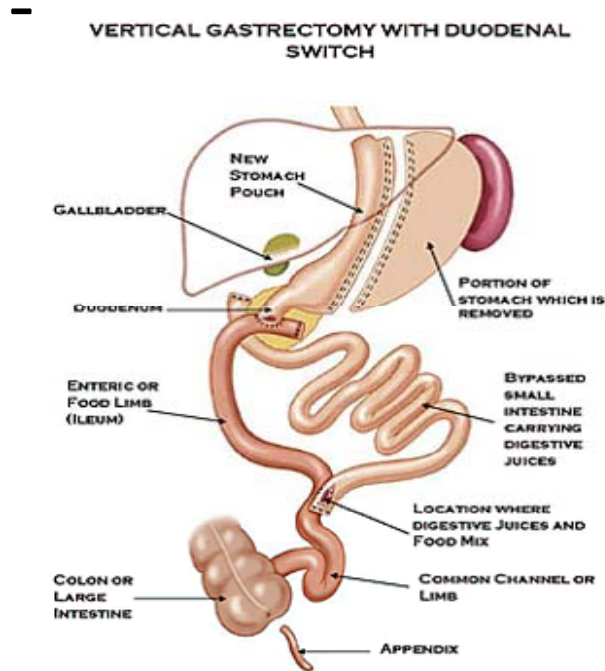






# Biliopancreatic Diversion with Duodenal Switch (DS)

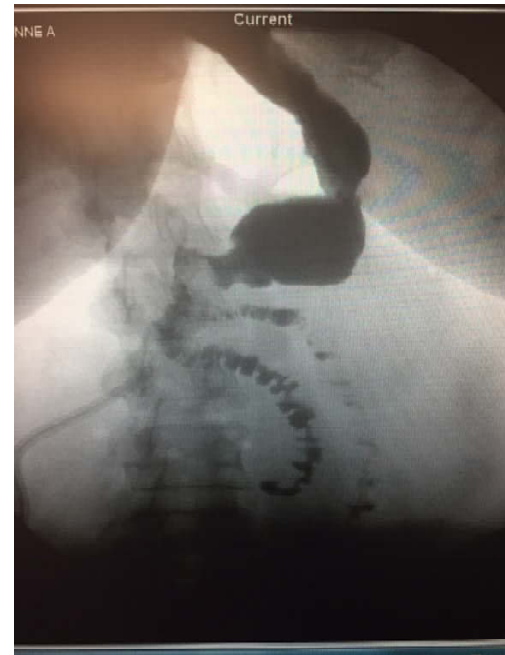
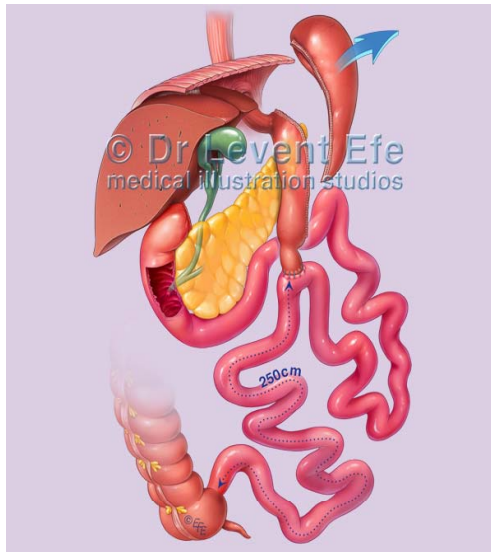- Normal anatomy





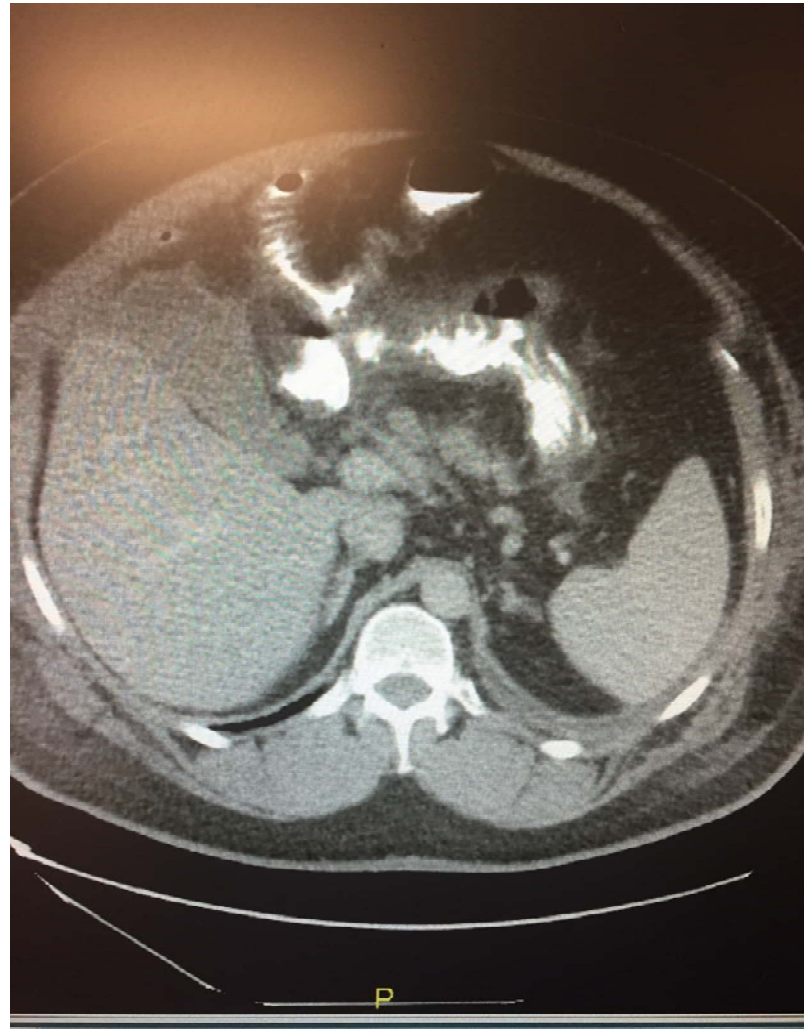
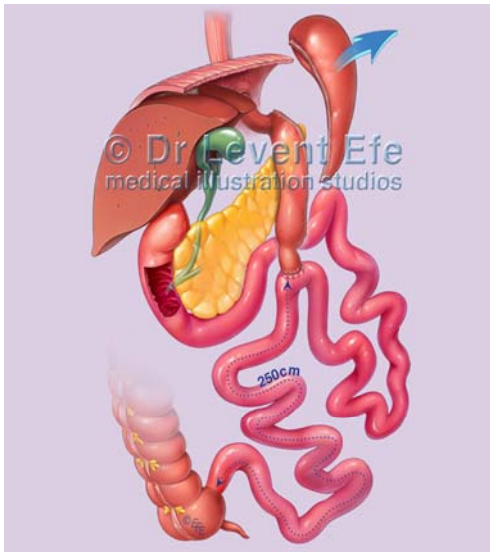# SADI

- Single anastomosis with duodenal interposition (Loop DS)
  - Normal anatomy



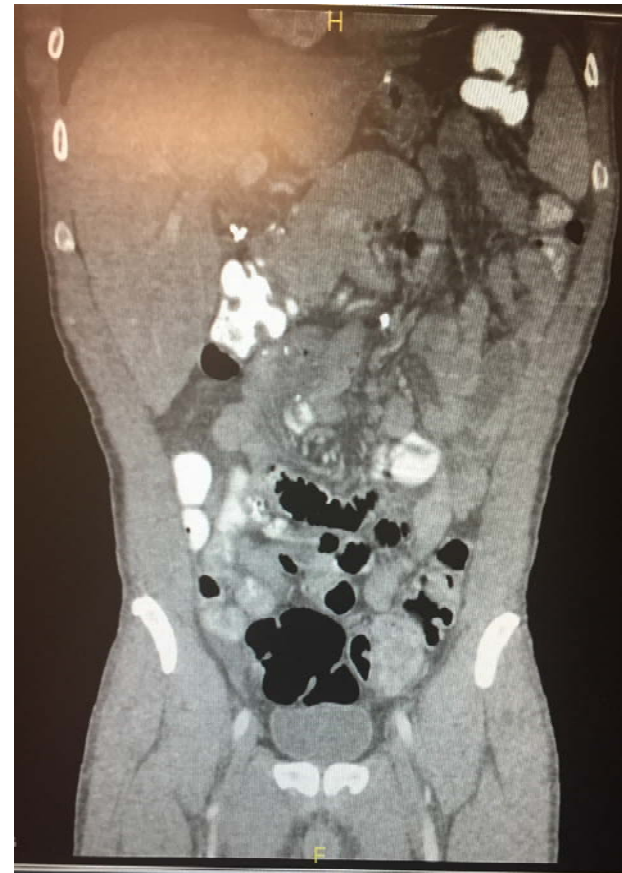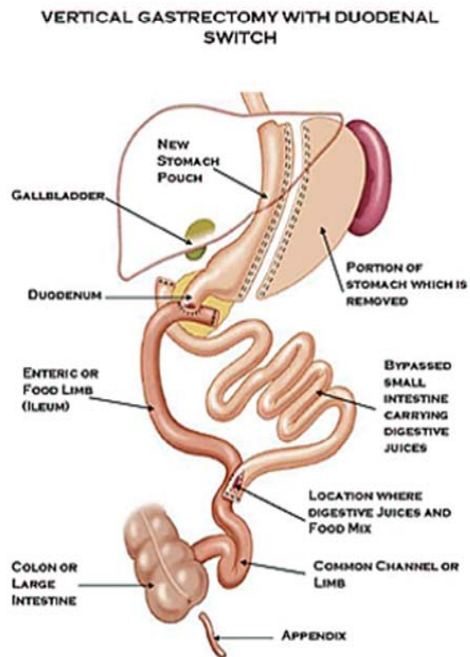
# DS and SADI

- Complications
  - Early-Leak



# DS and SADI

- Complications
  - Late- internal hernia

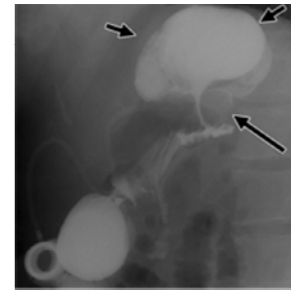




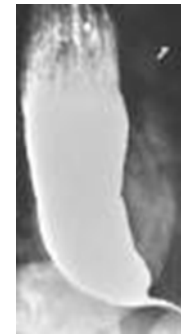# Revision Surgery

- Band needs removal
  - Preop UGI- What is the surgeon looking for?

1. Pouch dilatation



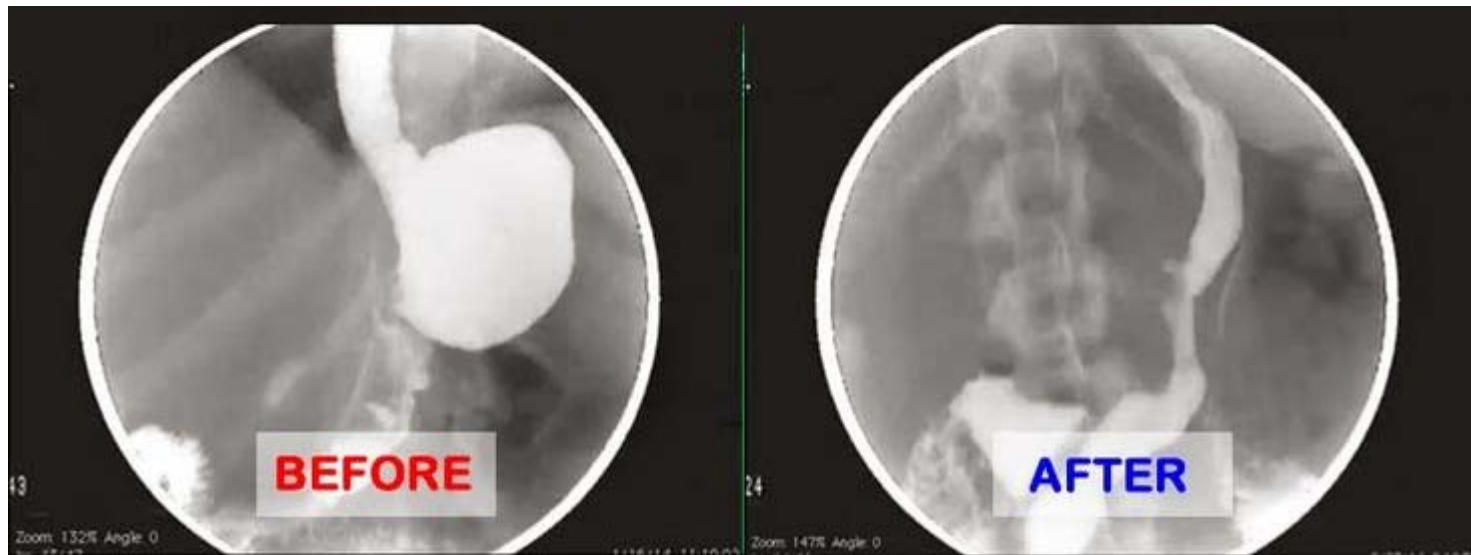
2. Esophageal dilatation



3. Reflux

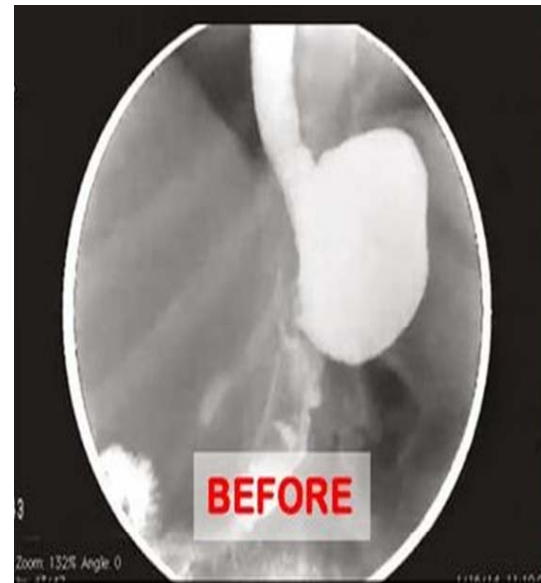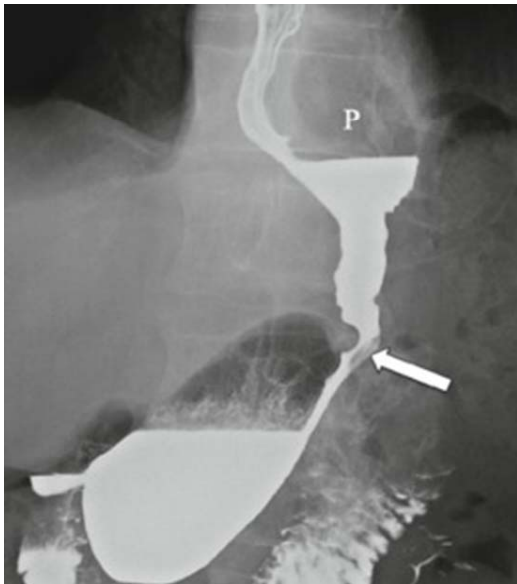# Revision Surgery

- Weight Loss Failure with Sleeve
  1. Retained fundus



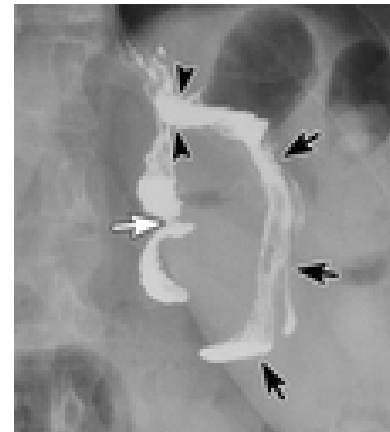
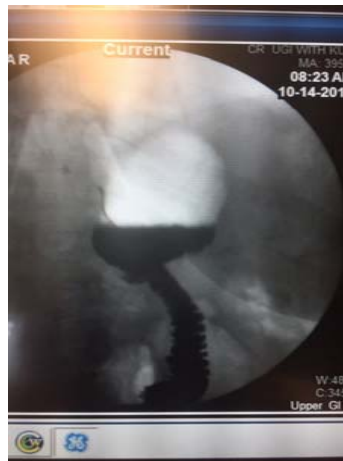# Revision Surgery

- Sleeve gastrectomy with GERD
  - Stenosis at angularis
  - Retained fundus



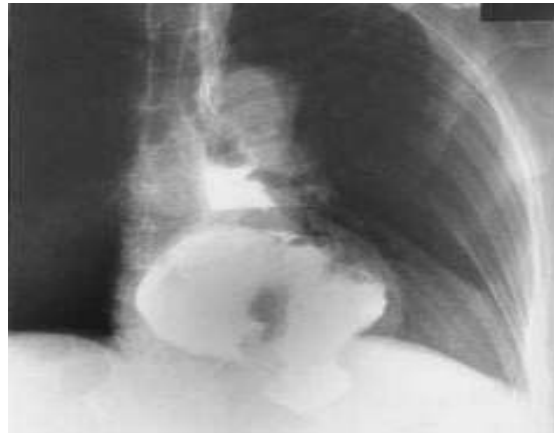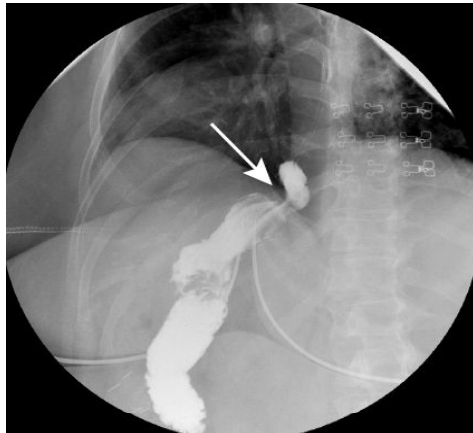
# Revision Surgery

- Gastric Bypass with weight loss failure or regain
  - Large gastric pouch (>60 ml)
  - Gastro-gastric fistula (cannot be identified simply by seeing contrast in bypassed stomach on CT)



# Revision Surgery

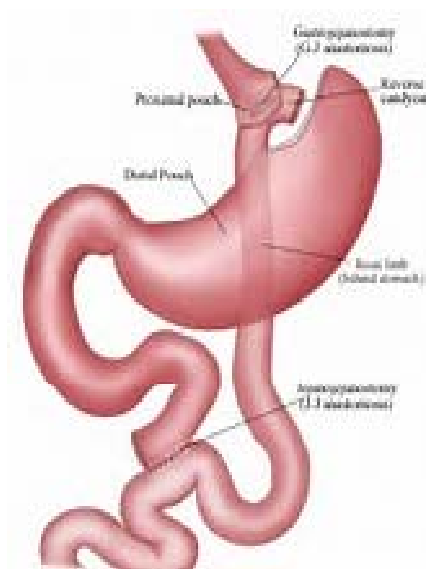
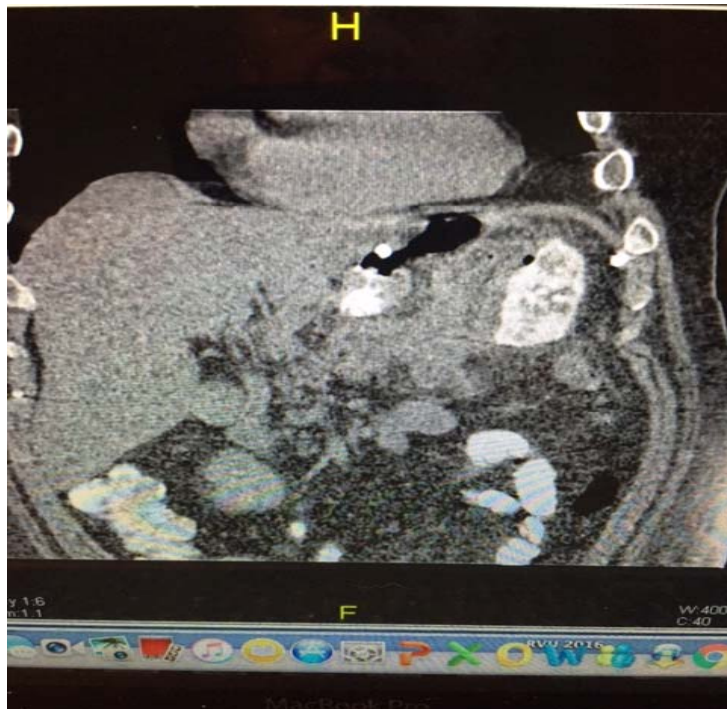- GERD after Gastric Bypass
  - Hiatal hernia containing gastric pouch



- Stenosis of G-J

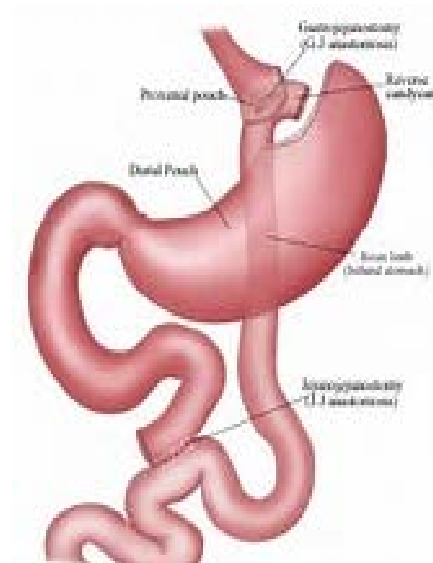
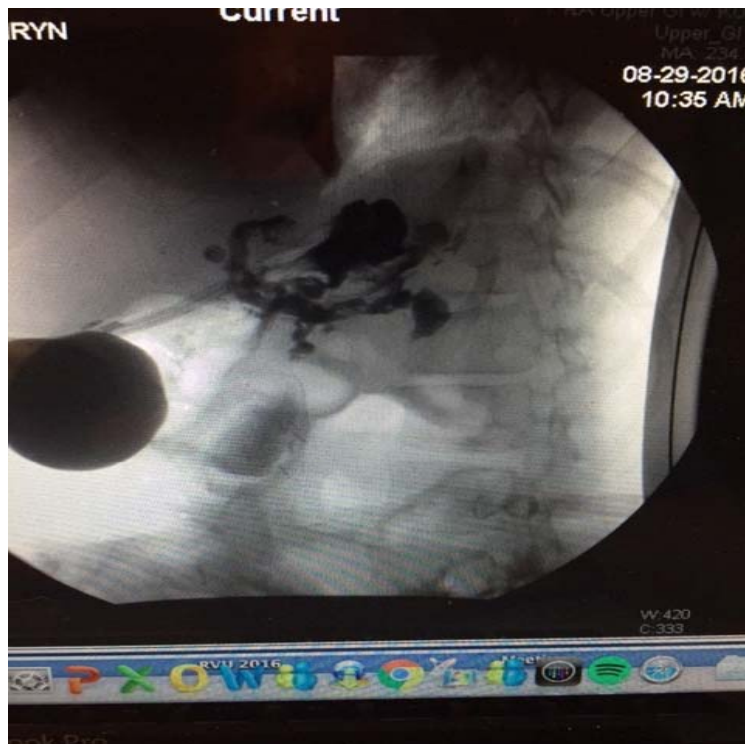# Miscellaneous

- Leak after conversion of gastric band erosion to gastric bypass



# Miscellaneous

- Leak after reversal of gastric bypass



# Questions

