

# Imaging of Abdominal pain and liver disease

**An algorithm for ordering and understanding the appropriate imaging modalities that are currently available. New and emerging technologies.**

David Kenny, D.O.

# Abdominal Pain

- Common presenting complaint
- Emergent acute pain?
- What diagnostic imaging is available and appropriate?  
What's a waste of time?
- What will the insurance company approve?

# Definition: Acute abdominal pain

- An acute abdomen refers to any condition within the abdomen which requires immediate surgical attention
- However, not all causes are abdominal, nor do all causes need surgery
- Most patients with abdominal pain probably have gastroenteritis

# Differential Diagnosis

- Ureteral calculi
- Acute appendicitis
- SBO
- Perforated bowel
- Crohn disease
- Ischemic colitis
- Pancolitis
- Diverticulitis
- Mesenteric panniculitis
- Peptic ulcer
- Esophagitis
- Epiploic appendigitis
- Mesenteric adenitis
- Segmental omental infarction
- AAA rupture
- Pyelonephritis
- PID
- Ruptured hemorrhagic cyst
- Ectopic pregnancy
- Ovarian torsion
- Irritable colon
- Incarcerated hernia

# Reducing Emergency Department Overuse: A \$38 Billion Opportunity

## Opportunity

Emergency department overuse: \$38 billion in wasteful health care spending



An increasing number of people are using hospital emergency departments (ED) for non-urgent care and for conditions that could have been treated in a primary care setting. Nationally, 56 percent, or roughly 67 million visits, are potentially avoidable.<sup>2</sup> Reducing this trend represents a significant opportunity to improve quality and lower costs in health care.

### Significant Savings

- The average cost of an ED visit is \$580 more than the cost of an office health care visit.<sup>3</sup>

### Who uses the ED for non-urgent care?

- All payer and age groups.
- Insured patients with a usual source of primary care.

## Solutions

**67** million, or more than half of the 120 million annual emergency visits, are potentially avoidable

Increasing access to primary care services can reduce emergency department overuse by up to 56 percent. A number of tested measures already exist, including offering alternative approaches to primary care, specialized services for vulnerable populations, and effective chronic disease management.

### Quality Improvements

#### Improved Access to Primary Care Services

- **Patient-Centered Health Care Home:** Early data from health care home pilots have observed a 37 percent reduction in ED use.<sup>4</sup>
- **Weekend Hours:** Patients receiving care from a primary care practice offering weekend hours use the ED 20 percent less than patients from practices that do not.<sup>5</sup>
- **Telephone Consultation:** 24-hour access to a physician telephone service reduced avoidable ED use from 41 percent of visits to 8 percent of visits.<sup>6</sup>

## Drivers for Change

- Payment Reform for Providers
- Financial Incentives for Patients
- Improved Data on Emergency Department Utilization

Reducing the overuse of emergency department services requires policy actions that involve providers, payers, and patients.

### Action Steps

#### Payment Reform for Providers

- Adopt payment approaches to enable providers to invest in primary care improvements such as extended hours, increased contact with patients via telephone and e-mail, health information technology, and additional staff for care teams.
- Implement performance-based payment systems that use patient ED utilization or appointment wait times as quality metrics to reward health care professionals who reduce ED overuse.

#### Financial Incentives for Patients

- Reduce co-payments for patients who use urgent care clinics.
- Increase patient co-payments for non-urgent ED visits.

#### Improved Data on ED Utilization

In order to report accurate and up-to-date information to providers on their patients'

Primary Care  
treating more  
acute illnesses

# ACR Appropriateness criteria

<http://www.acr.org/Quality-Safety/Appropriateness-Criteria>

## Evidence based guidelines

- Most appropriate decision: enhancing quality
- Developed by expert panels in 1994
- ACR Select licensed software product used to be incorporated into EHR and computerized order entry.



# Clinical Decision Support Software

- Appropriate use, imaging and therapy
- Declining reimbursement push for clinical decision support software
- Telling you what to do? and how/when to do it.
- Integrated workflow accepted by doctors
- Meeting appropriateness guidelines, reducing unnecessary tests.....reducing HC cost
- Cost.....MU 2
- Already in place in many hospital systems

# Modalities for Abdominal Pain

What imaging modalities are available and when do we use them?

- X-ray ( including fluoroscopy)
- Ultrasound
- CT
- MRI
- Nuclear medicine



# Abdominal Pain

Gastrointestinal		
Topic Name	Narrative	Evidence Table
Acute (Nonlocalized) Abdominal Pain and Fever or Suspected Abdominal Abscess	 <a href="#">Narrative</a>	 <a href="#">Evidence Table</a>
Acute Pancreatitis	 <a href="#">Narrative</a>	 <a href="#">Evidence Table</a>
Blunt Abdominal Trauma	 <a href="#">Narrative</a>	 <a href="#">Evidence Table</a>
Colorectal Cancer Screening	 <a href="#">Narrative</a>	 <a href="#">Evidence Table</a>
Crohn Disease	 <a href="#">Narrative</a>	 <a href="#">Evidence Table</a>
Dysphagia	 <a href="#">Narrative</a>	 <a href="#">Evidence Table</a>
Jaundice	 <a href="#">Narrative</a>	 <a href="#">Evidence Table</a>
Left Lower Quadrant Pain — Suspected Diverticulitis	 <a href="#">Narrative</a>	 <a href="#">Evidence Table</a>
Liver Lesion — Initial Characterization	 <a href="#">Narrative</a>	 <a href="#">Evidence Table</a>
Palpable Abdominal Mass	 <a href="#">Narrative</a>	 <a href="#">Evidence Table</a>
Pretreatment Staging of Colorectal Cancer	 <a href="#">Narrative</a>	 <a href="#">Evidence Table</a>
Right Lower Quadrant Pain — Suspected Appendicitis	 <a href="#">Narrative</a>	 <a href="#">Evidence Table</a>
Right Upper Quadrant Pain	 <a href="#">Narrative</a>	 <a href="#">Evidence Table</a>
Suspected Liver Metastases	 <a href="#">Narrative</a>	 <a href="#">Evidence Table</a>
Suspected Small-Bowel Obstruction	 <a href="#">Narrative</a>	 <a href="#">Evidence Table</a>

# Imaging Strategy

CT most common and appropriate modality

Ultrasound second most common

MRI/X-ray/HIDA

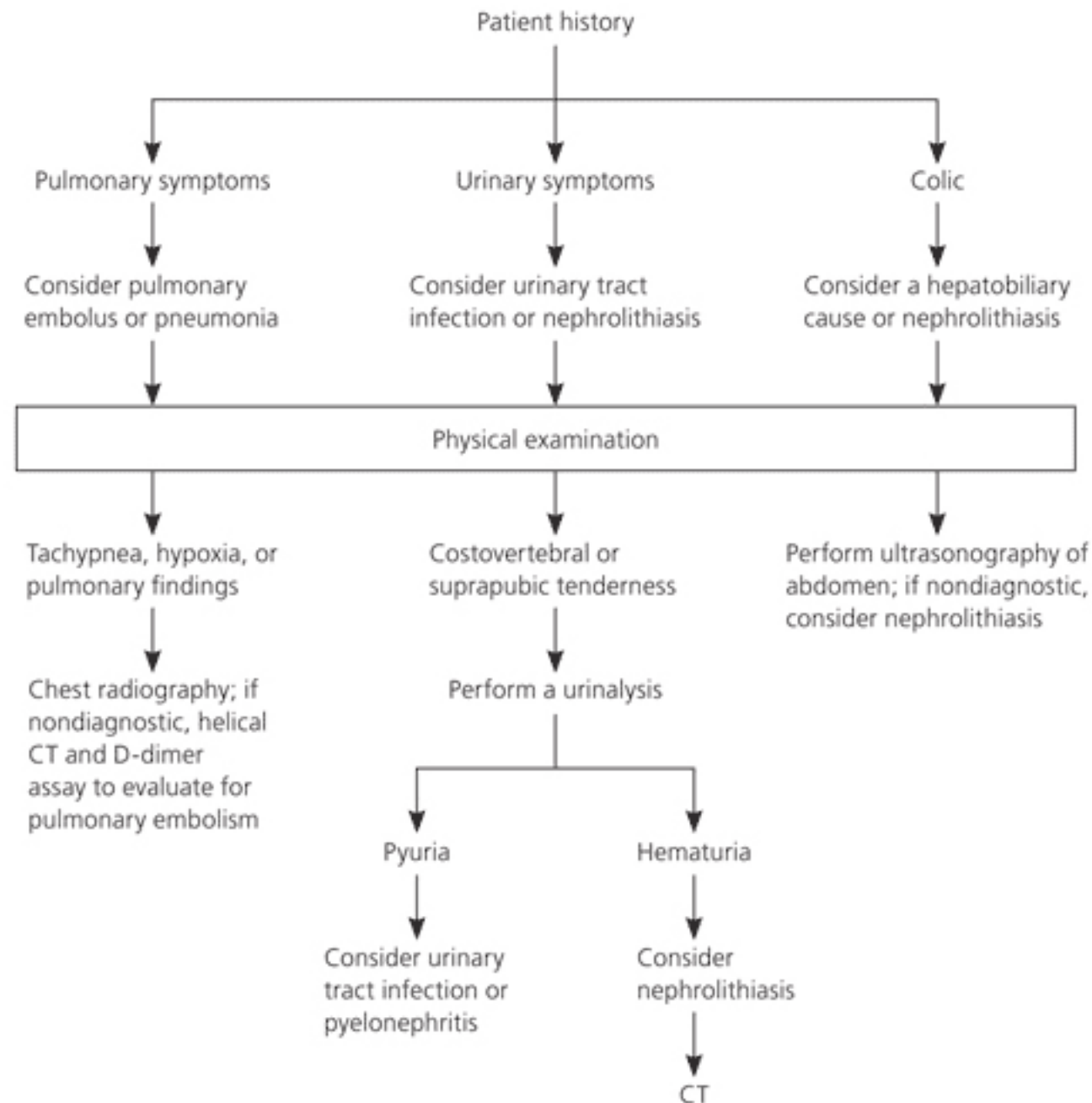
# Acute (non-localized) abdominal pain and fever, (possible or suspected abscess) no recent operation

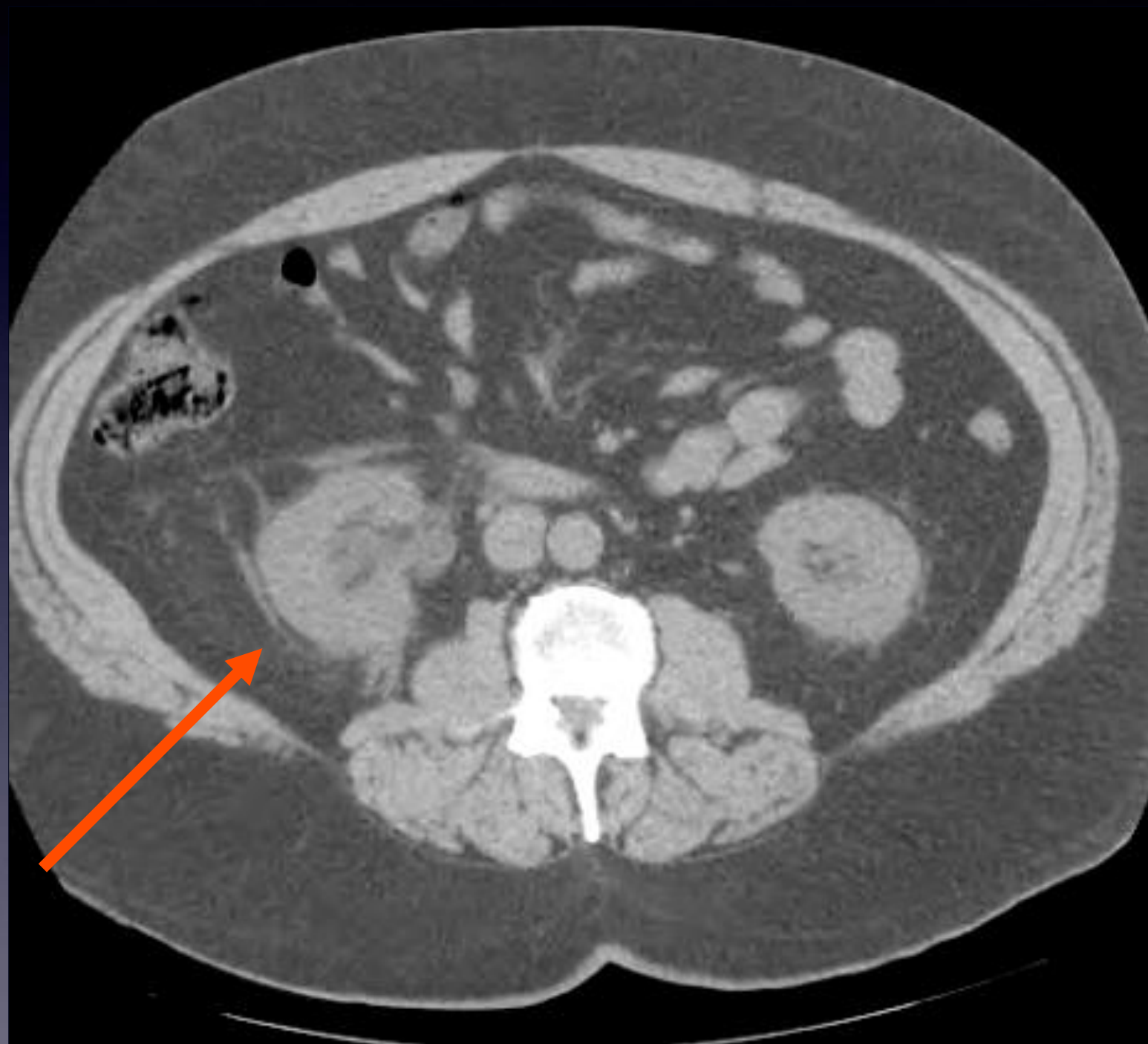Radiologic Procedure	Rating	Comments	<u>RRL*</u>
CT abdomen and pelvis with contrast	8		☢☢☢☢☢
CT abdomen and pelvis without contrast	6		☢☢☢☢☢
US abdomen	6		O
X-ray abdomen	6	To evaluate for bowel perforation.	☢☢
MRI abdomen and pelvis without contrast	5		O
MRI abdomen and pelvis without and with contrast	5	See statement regarding contrast in text under “Anticipated Exceptions.”	O
X-ray upper GI series with small bowel follow-through	4		☢☢☢☢
X-ray contrast enema	4		☢☢☢☢
CT abdomen and pelvis without and with contrast	3	May be helpful in select cases but should be used with caution because of increased radiation dose.	☢☢☢☢☢
Ga-67 scan abdomen	3		☢☢☢☢☢
Tc-99m WBC scan abdomen and pelvis	3		☢☢☢☢☢
In-111 WBC scan abdomen and pelvis	3		☢☢☢☢☢
<b><u>Rating Scale:</u> 1,2,3 Usually not appropriate; 4,5,6 May be appropriate; 7,8,9 Usually appropriate</b>			<b>*Relative Radiation Level</b>

# Location

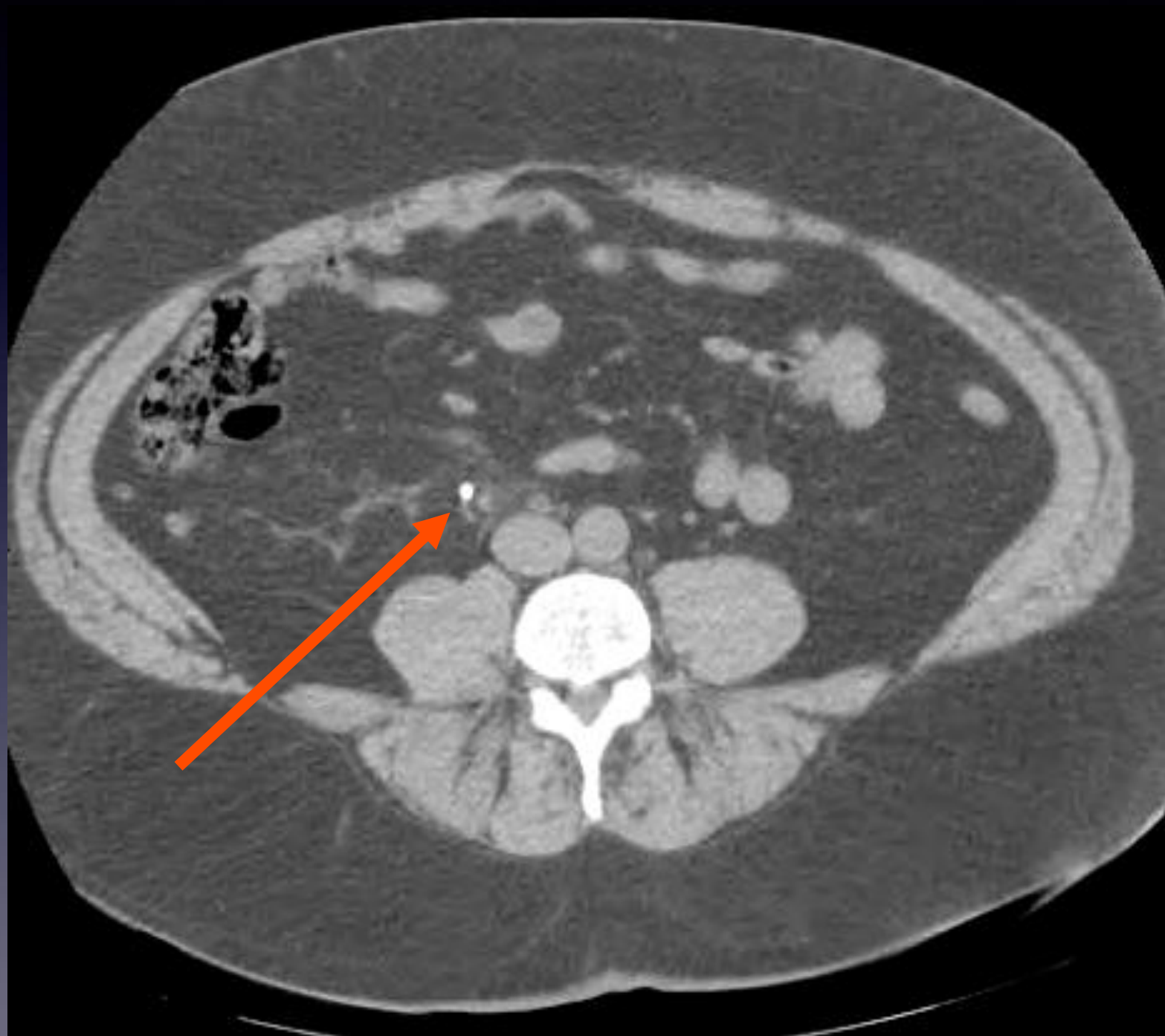
- RUQ: cholecystitis, duodenal ulcer
- Upper mid: peptic ulcer, gastritis, esophagitis
- LUQ: gastroenteritis, pancreatitis
- RLQ: muscle strain, appendicitis, PID
- LLQ: diverticulitis
- Lower mid: appendicitis, SBO, gastroenteritis

# RUQ Pain









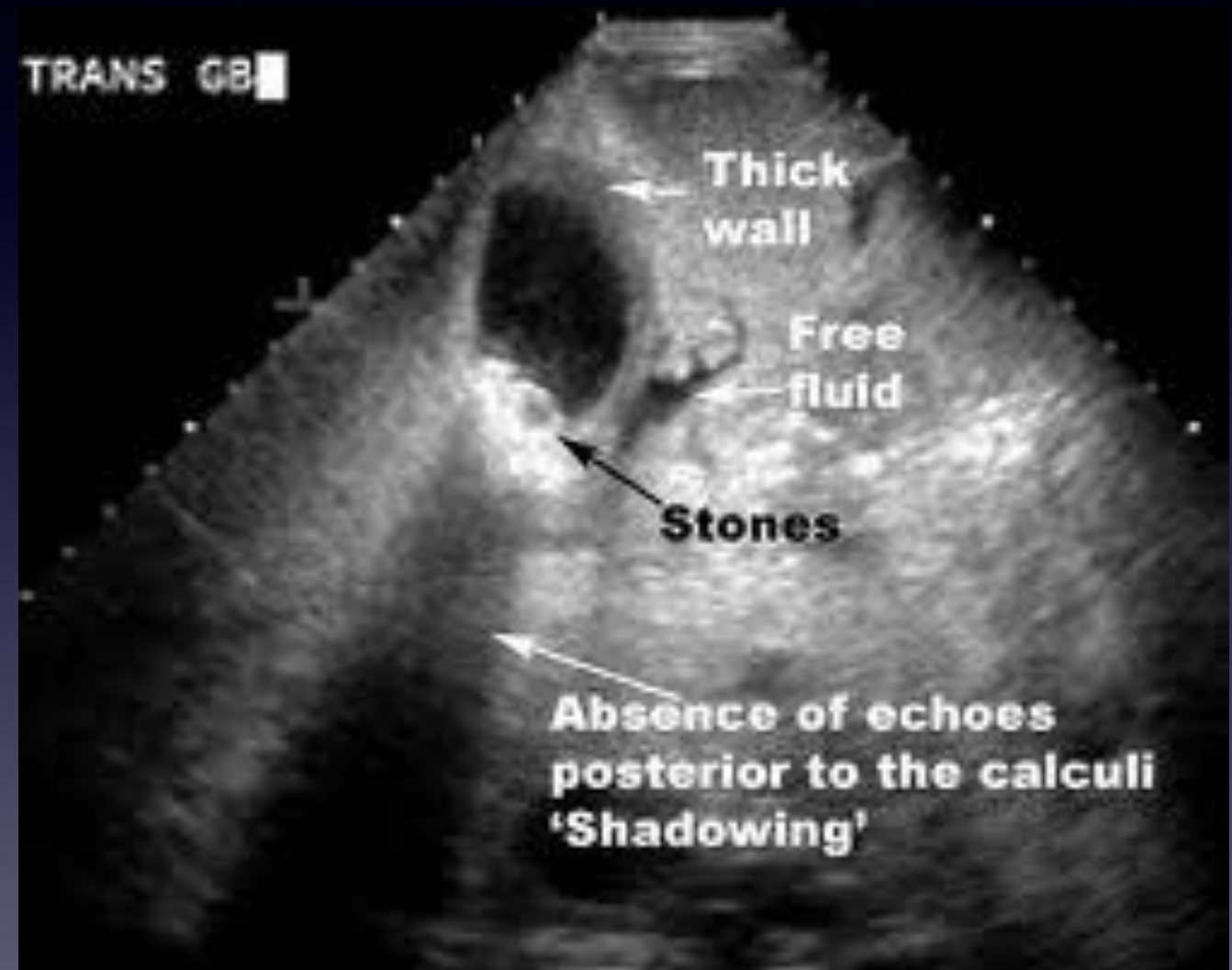# Ureteral Calculi

- Clinical: spasmodic pain increasing and decreasing in severity, usually in flank
- Hematuria is common (appr. 85%)
- Imaging
  - X-ray 45% sensitive
  - CT 98% sensitive and specific
- 16-45% of patients with flank pain have extra-urinary disease, therefore IVP not indicated

# RUQ pain suspected biliary colic

90 to 95 % obstruction of the  
gallbladder neck or cyst duct

Ultrasound is the preferred modality  
wall thickening, calculi and pain with  
compression



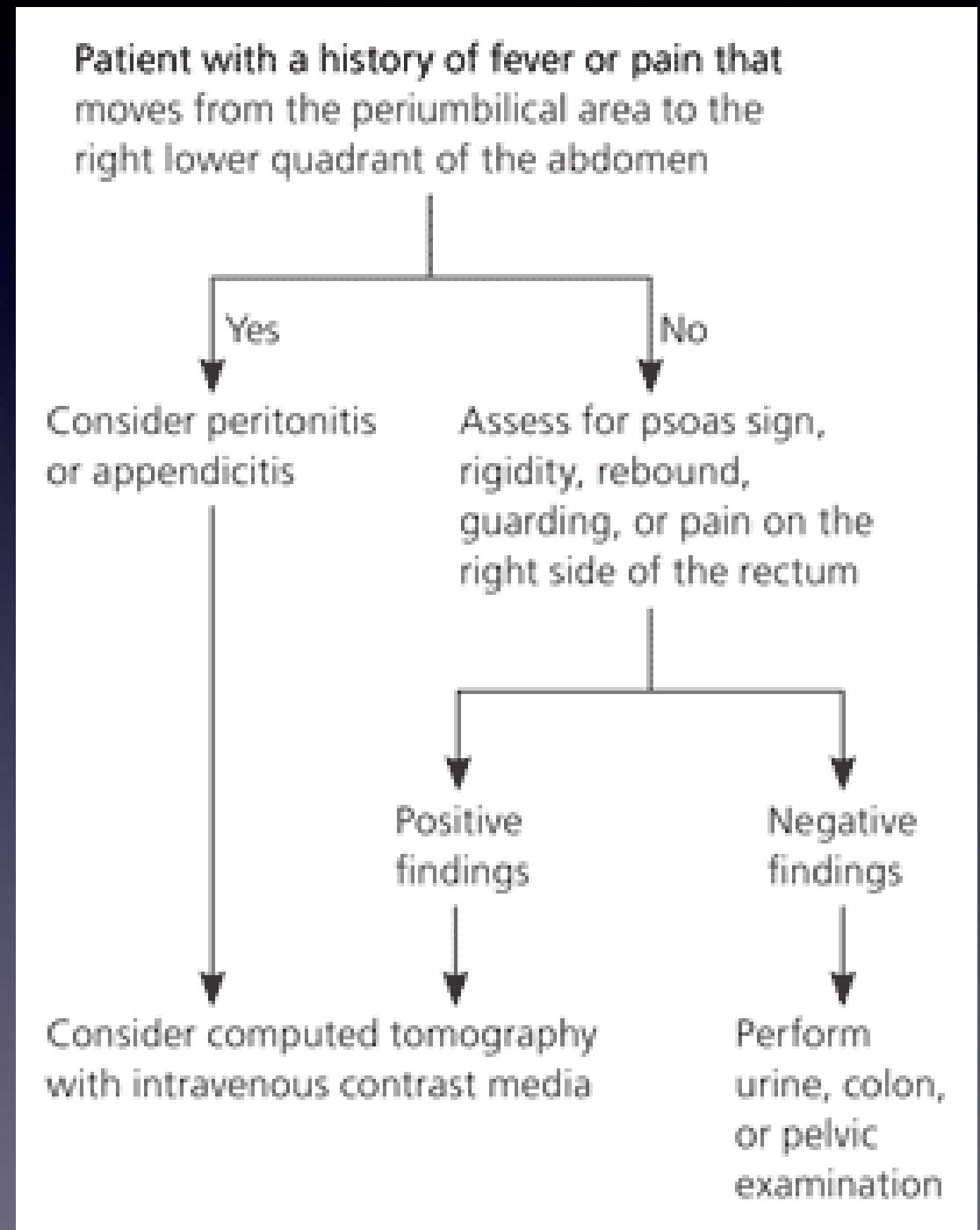
# ACR

**Clinical Condition:** Right Upper Quadrant Pain

**Variant 1:** Fever, elevated white blood cell count (WBC), positive Murphy sign.

Radiologic Procedure	Rating	Comments	<u>RRL*</u>
US abdomen	9		O
MRI abdomen without and with contrast	6	See statement regarding contrast in text under "Anticipated Exceptions."	O
Cholescintigraphy	6	Based on US findings, this generally should follow US of the right upper quadrant.	☢ ☢
CT abdomen with contrast	6		☢ ☢ ☢
MRI abdomen without contrast	4		O
CT abdomen without contrast	4		☢ ☢ ☢
CT abdomen without and with contrast	3		☢ ☢ ☢ ☢
<b><u>Rating Scale:</u> 1,2,3 Usually not appropriate; 4,5,6 May be appropriate; 7,8,9 Usually appropriate</b>			<b>*Relative Radiation Level</b>

# RLQ pain



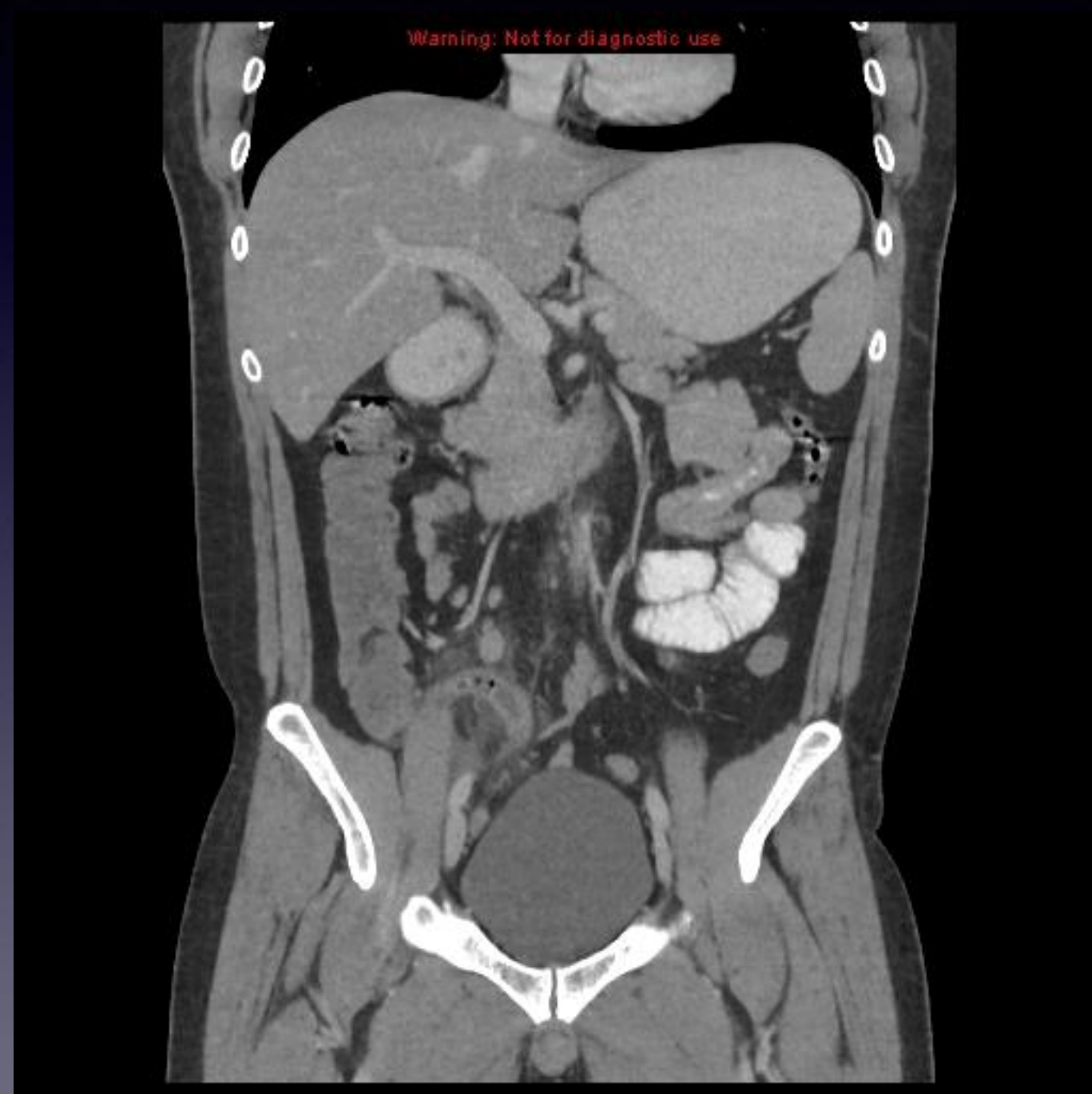

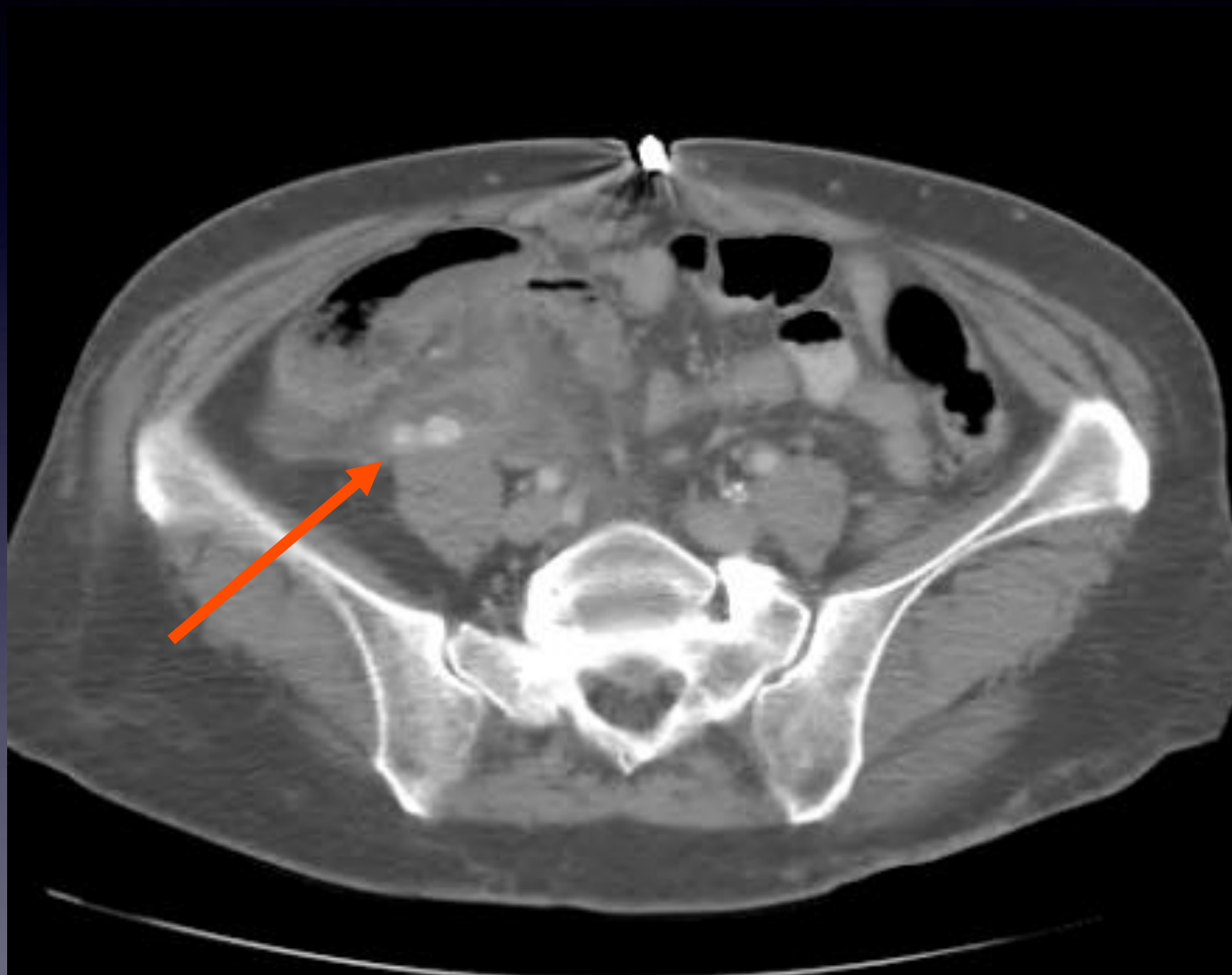**Clinical Condition:** Right Lower Quadrant Pain—Suspected Appendicitis

**Variant 1:** Fever, leukocytosis, and classic clinical presentation for appendicitis in adults.

Radiologic Procedure	Rating	Comments	<u>RRL*</u>
CT abdomen and pelvis with contrast	8	Oral or rectal contrast may not be needed depending on institutional preference.	☢ ☢ ☢ ☢
CT abdomen and pelvis without contrast	7	Use of oral or rectal contrast depends on institutional preference.	☢ ☢ ☢ ☢
US abdomen	6	Perform this procedure with graded compression.	O
US pelvis	5	This procedure is appropriate in women with pelvic pain.	O
MRI abdomen and pelvis without and with contrast	5	See statement regarding contrast in text under “Anticipated Exceptions.”	O
X-ray abdomen	4	This procedure may be useful when there is concern for perforation and free air.	☢ ☢
CT abdomen and pelvis without and with contrast	4	Oral or rectal contrast may not be needed in this procedure depending on institutional preference.	☢ ☢ ☢ ☢
MRI abdomen and pelvis without contrast	4		O
X-ray contrast enema	2		☢ ☢ ☢
Tc-99m WBC scan abdomen and pelvis	2		☢ ☢ ☢ ☢
<b><u>Rating Scale:</u> 1,2,3 Usually not appropriate; 4,5,6 May be appropriate; 7,8,9 Usually appropriate</b>			<b>*Relative Radiation Level</b>



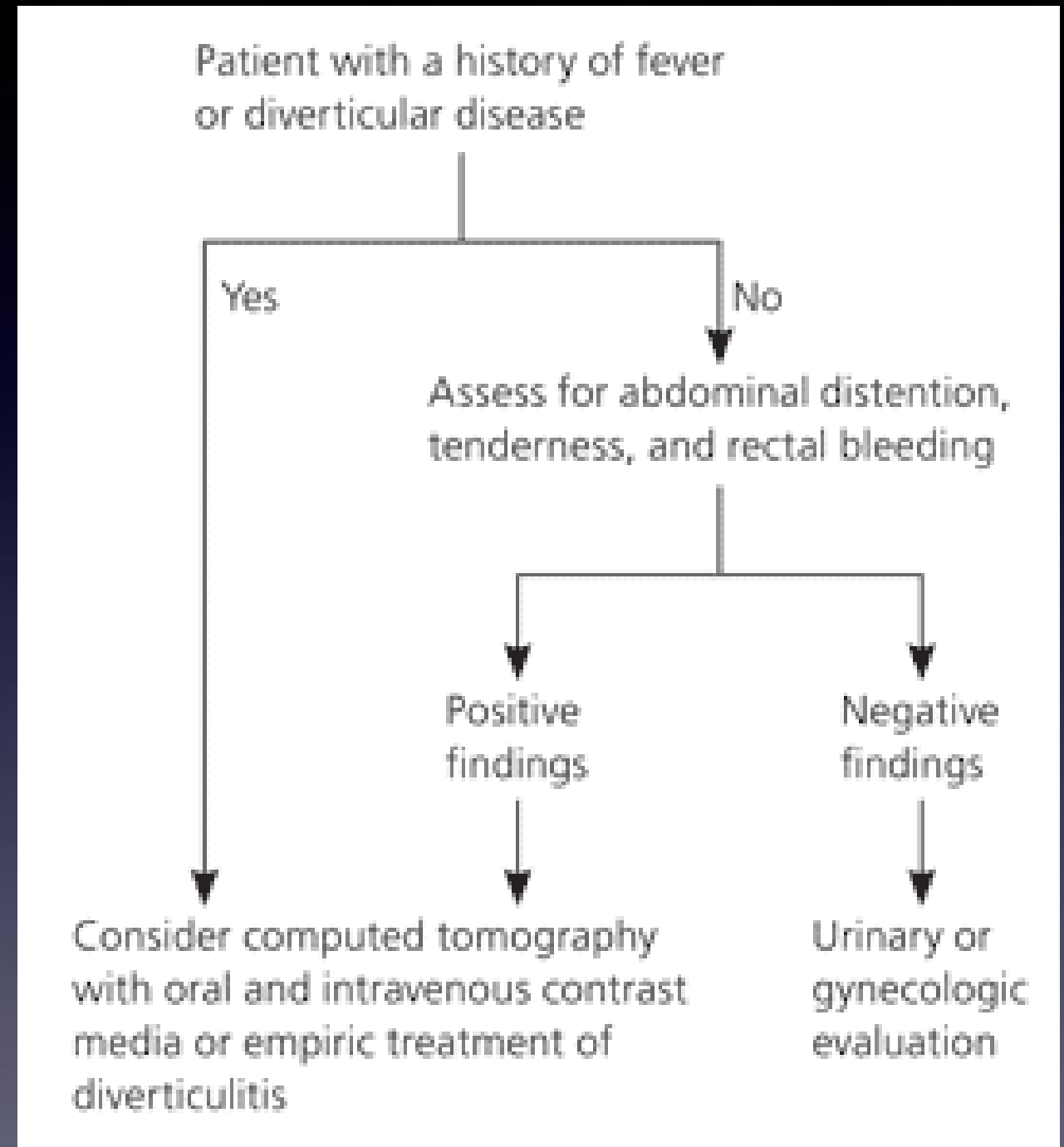




# Acute appendicitis

- Clinical:
  - Classically peri-umbilical then focal RLQ pain
  - Often clinical picture is confusing
  - Vomiting, constipation, fever are common
- CT 97% sensitive and 98% specific
- Usually surgical, but some cases treated with antibiotics prior to surgery
- Abscess can be treated percutaneously

# Algorithm LLQ pain



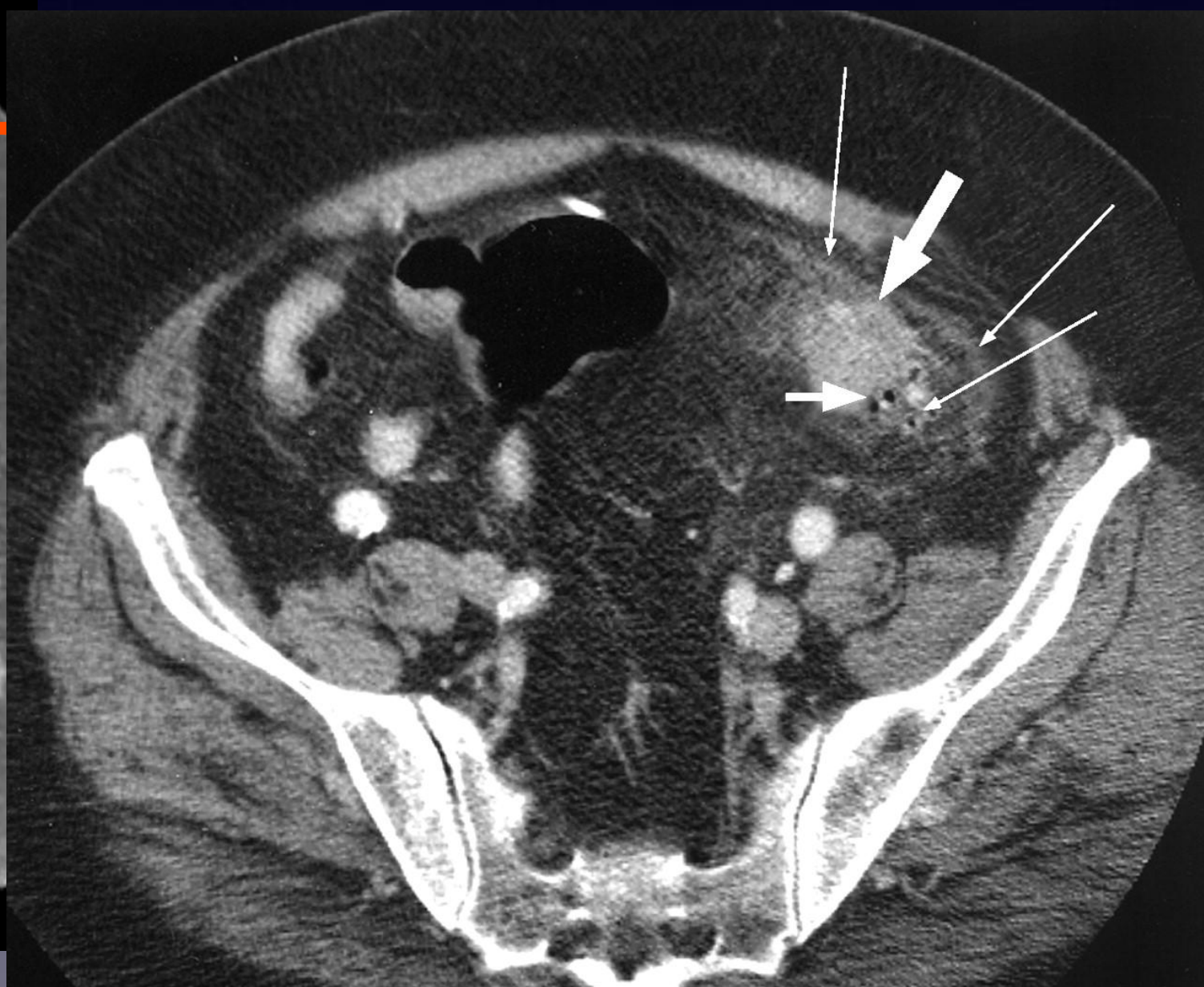
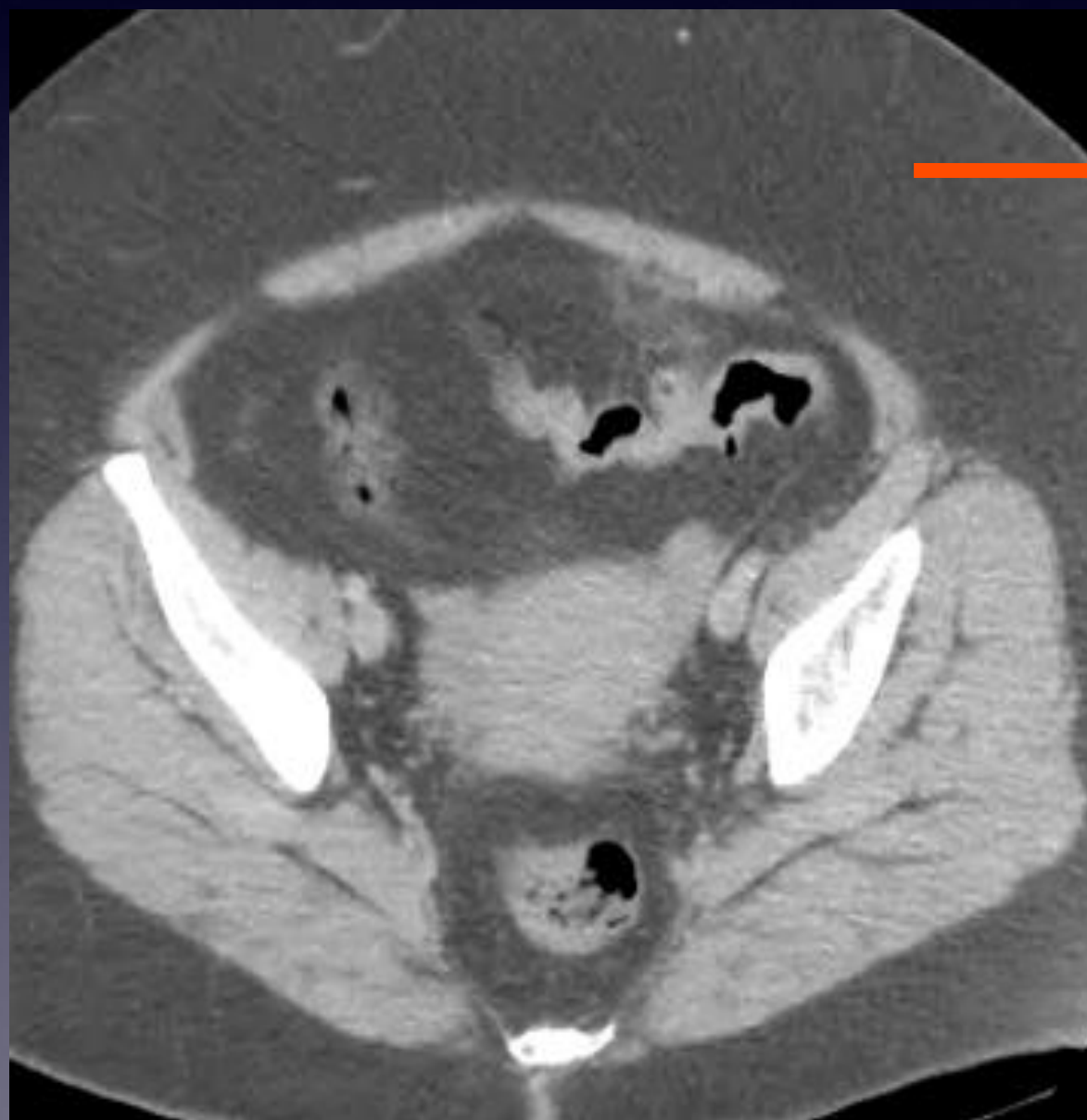## American College of Radiology ACR Appropriateness Criteria®

**Clinical Condition:**      Left Lower Quadrant Pain — Suspected Diverticulitis

**Variant 1:**              Typical clinical presentation for diverticulitis, suspected complications or atypical presentations.

Radiologic Procedure	Rating	Comments	<u>RRL*</u>
CT abdomen and pelvis with contrast	9	For this procedure oral and/or colonic contrast may be helpful for bowel luminal visualization.	⦿⦿⦿⦿
CT abdomen and pelvis without contrast	6		⦿⦿⦿⦿
CT abdomen and pelvis without and with contrast	5		⦿⦿⦿⦿
MRI abdomen and pelvis without contrast	5		O
MRI abdomen and pelvis without and with contrast	5	See statement regarding contrast in text under “Anticipated Exceptions.”	O
X-ray contrast enema	4		⦿⦿⦿
US abdomen transabdominal graded compression	4		O
X-ray abdomen and pelvis	4		⦿⦿⦿
US pelvis transvaginal	2		O
<b><u>Rating Scale:</u></b> 1,2,3 Usually not appropriate; 4,5,6 May be appropriate; 7,8,9 Usually appropriate			<b>*Relative Radiation Level</b>







# LUQ Pain

- Variety of clinical conditions
- No clear cut imaging recommendations ( No ACR appropriate category)
- Endoscopy is far more sensitive and specific than an Upper GI
- CT with oral and IV may be useful

# Differential Diagnosis

- Ureteral calculi
- Acute appendicitis
- SBO
- Perforated bowel
- Crohn disease
- Ischemic colitis
- Pancolitis
- Diverticulitis
- Mesenteric panniculitis
- Peptic ulcer
- Esophagitis
- Epiploic appendicitis
- Mesenteric adenitis
- Segmental omental infarction
- AAA rupture
- Pyelonephritis
- PID
- Ruptured hemorrhagic cyst
- Ectopic pregnancy
- Ovarian torsion
- Irritable colon
- Incarcerated hernia

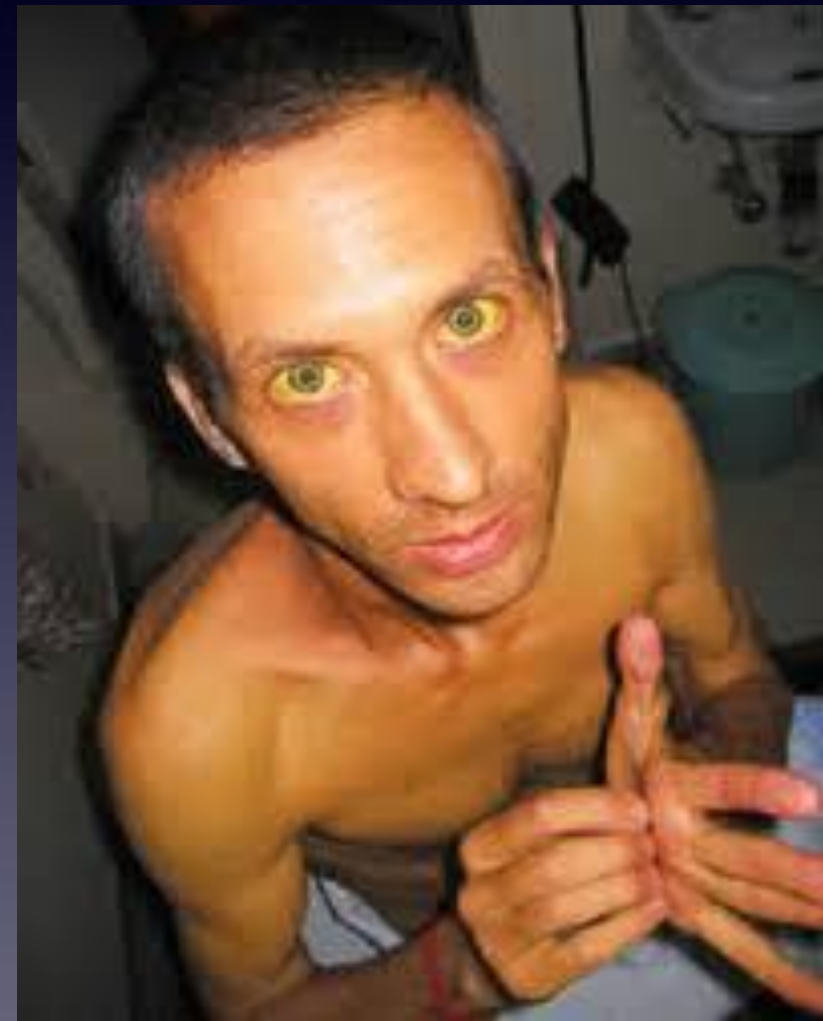# SUMMARY

- CT is the work horse of abdominal pain especially in the acute abdomen
- Before ordering the study you must decide if ureteral calculi are suspected
- Combination of history, physical and CT will usually place the patient in one of three categories: surgical, therapy, self-limited

# Abnormal Liver Function Tests

# My patient has abnormal liver function tests

- Mild elevations of ALT and AST are common in asymptomatic
- Most common: non alcoholic fatty liver disease....NASH
- Alcoholism, medication, viral, hemochromatosis
- Autoimmune, A1 antitrypsin, Wilson disease
- Others....



# Available Imaging Modalities

- Ultrasound
  - excellent first line exam
- Computed tomography
- HIDA & Liver Spleen scans
- MRI
- PET
- ERCP



# Useful Resources

- **ACR Appropriateness Criteria**

- [http://www.acr.org/secondarymainmenucategories/quality\\_safety/app\\_criteria.aspx](http://www.acr.org/secondarymainmenucategories/quality_safety/app_criteria.aspx)

- **The Right Imaging Study: A Guide For Physicians** by [Ronald L. Eisenberg](#), [Alexander R. Margulis](#), [Robert B. Taylor](#)

- **Web resources**

- **Uptodate**

- **Emedicine**

# 60 year old female

- Swollen abdomen
- Fatigue
- Jaundice
- Long history of alcohol abuse

**Increased Liver  
enzymes ETOH**

Ultrasound

Fatty  
Liver

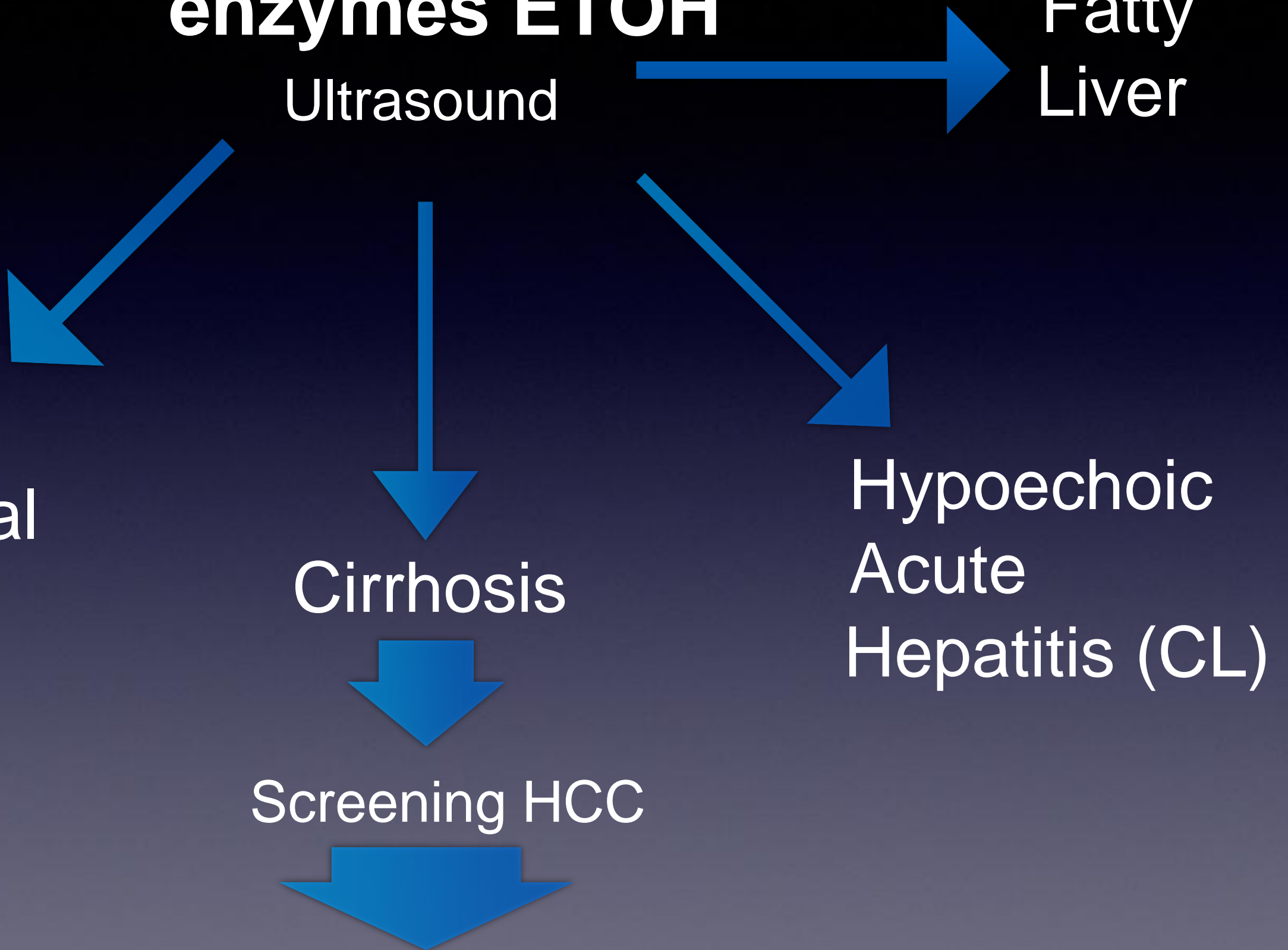
Normal

Cirrhosis

Hypoechoic  
Acute  
Hepatitis (CL)

Screening HCC

CT/MRI (Contrast 3 phase)



# Imaging Appearance Of Cirrhosis

- . Nodular surface contour
- . Left lateral lobe enlargement
- . Increased caudate to right lobe ratio
- . Relative appearance of medial left lobe atrophy
- . Paraumbilical venous collaterals/splenorenal shunt
- . Varices
  - . paraesophageal
  - . submucosal esophageal

# Ultrasound appearance of cirrhosis

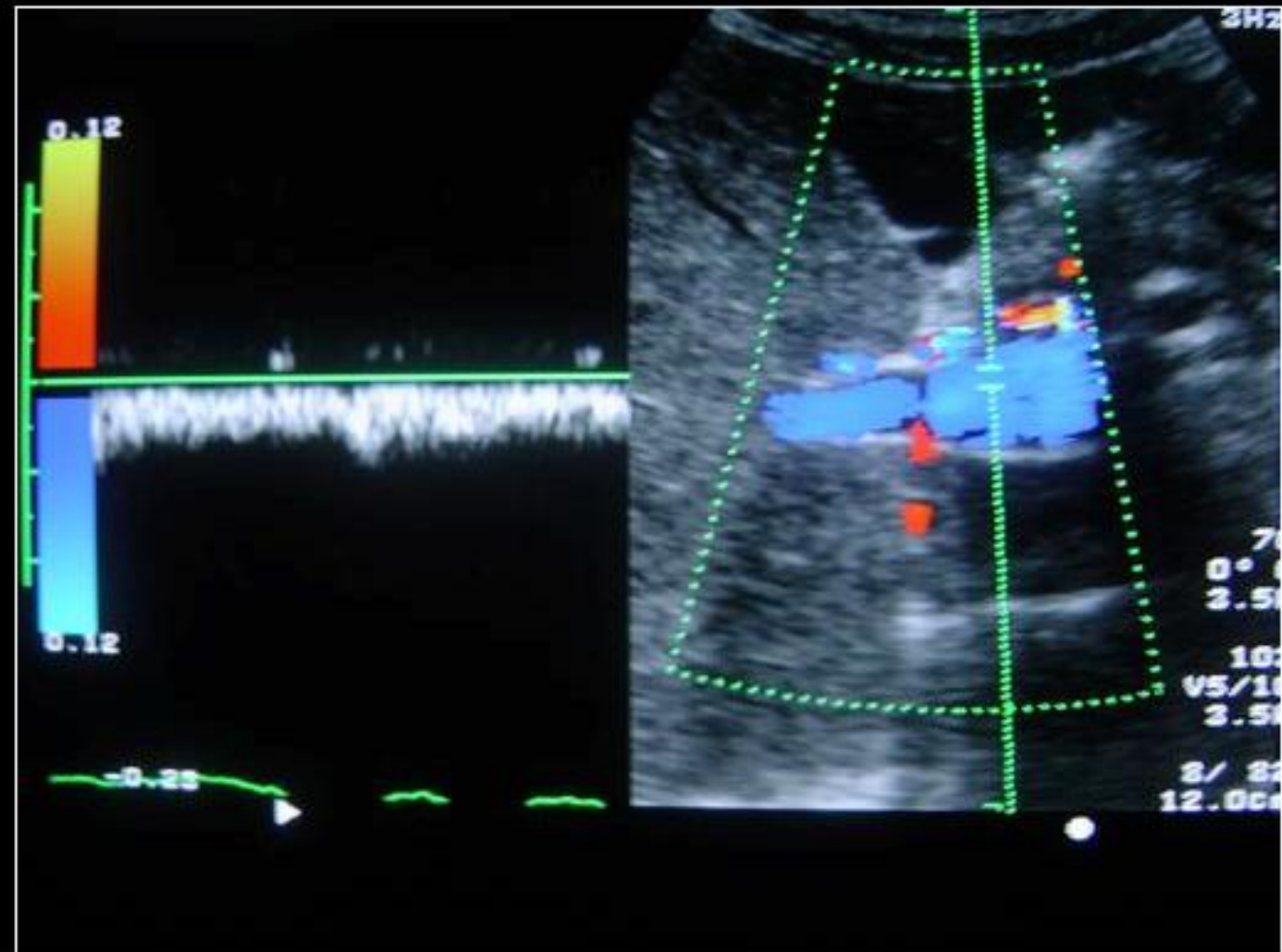
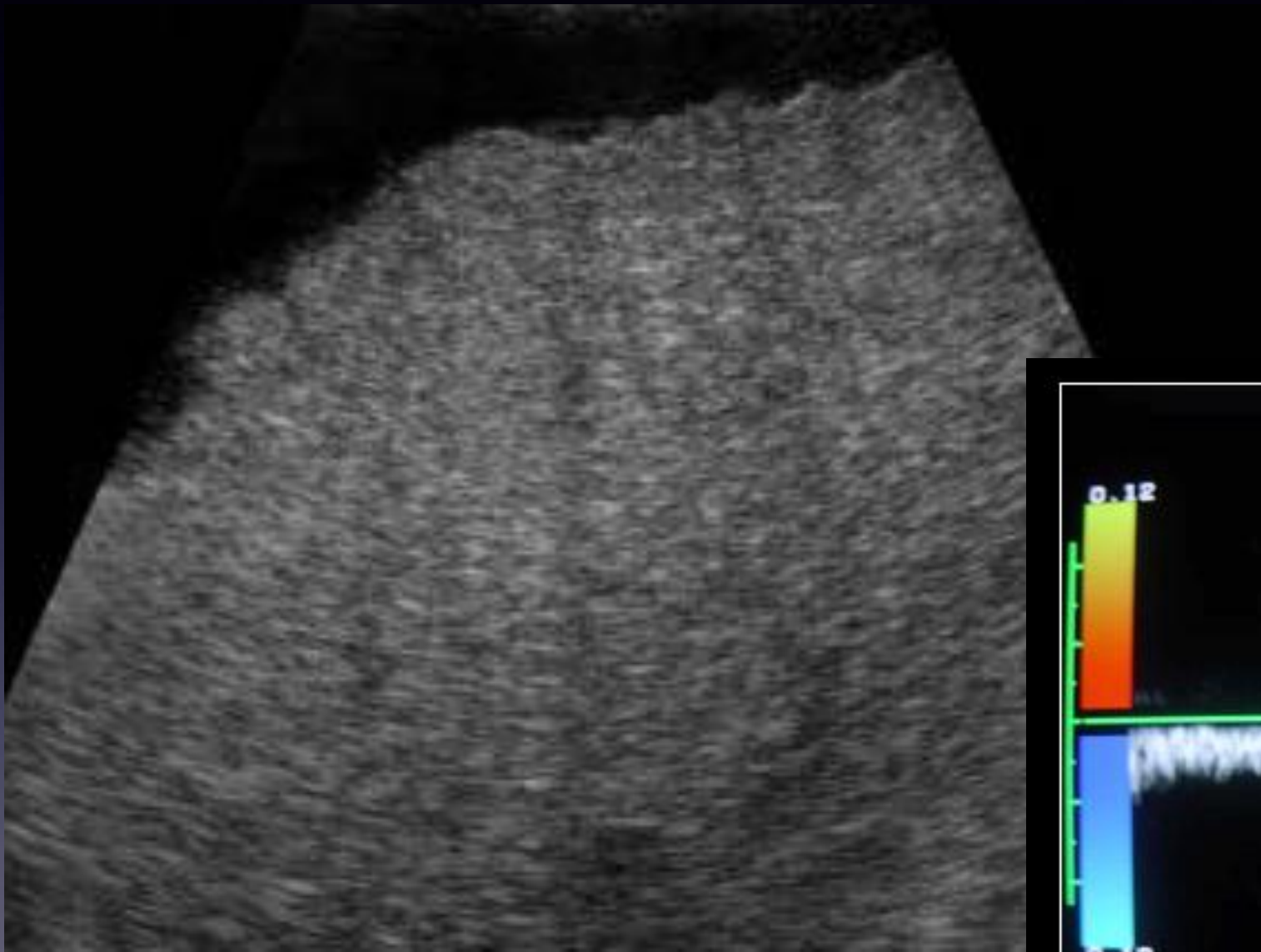
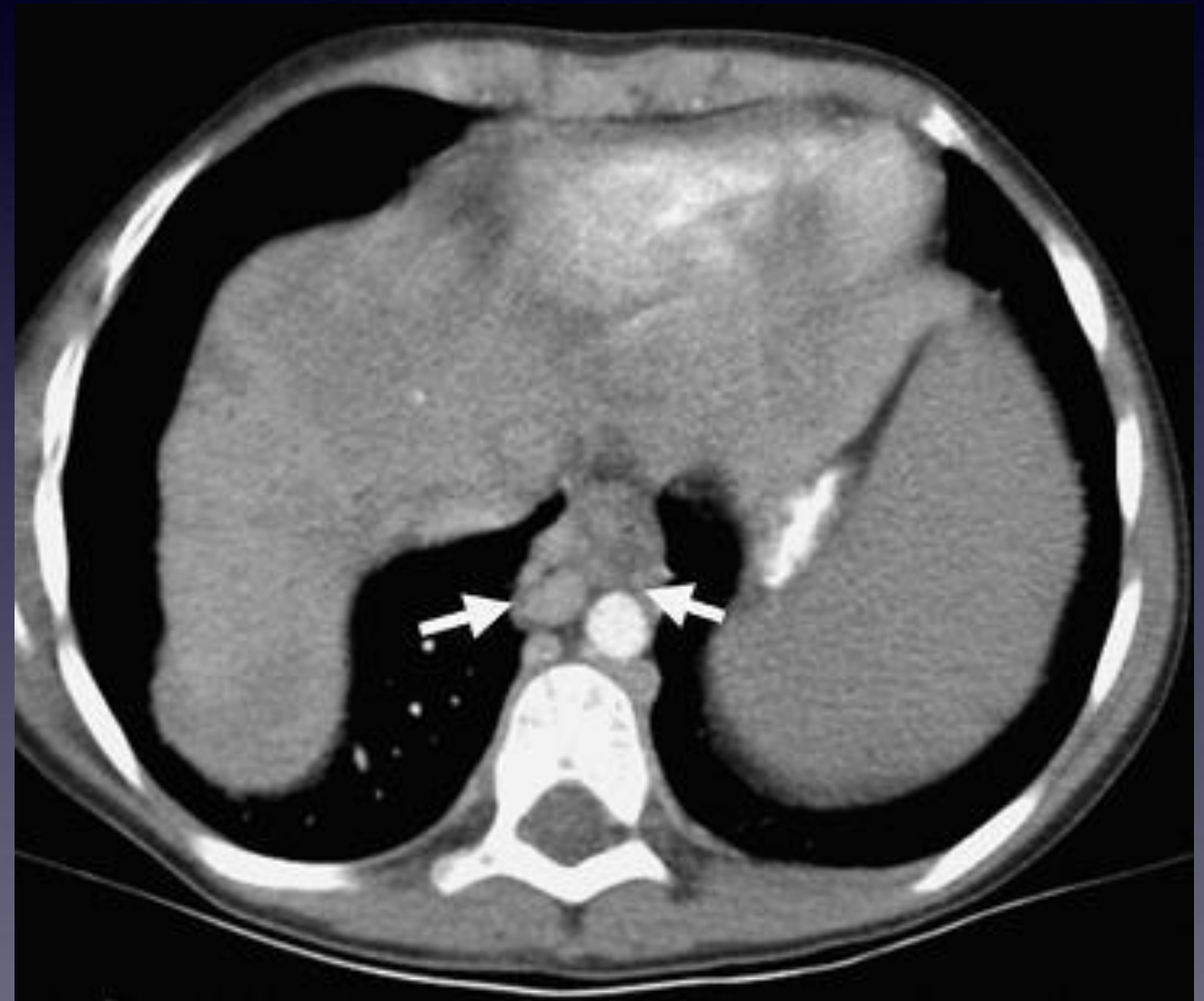

Fig. 2: HEPATOFUGAL FLOW IN CIRRHOSIS

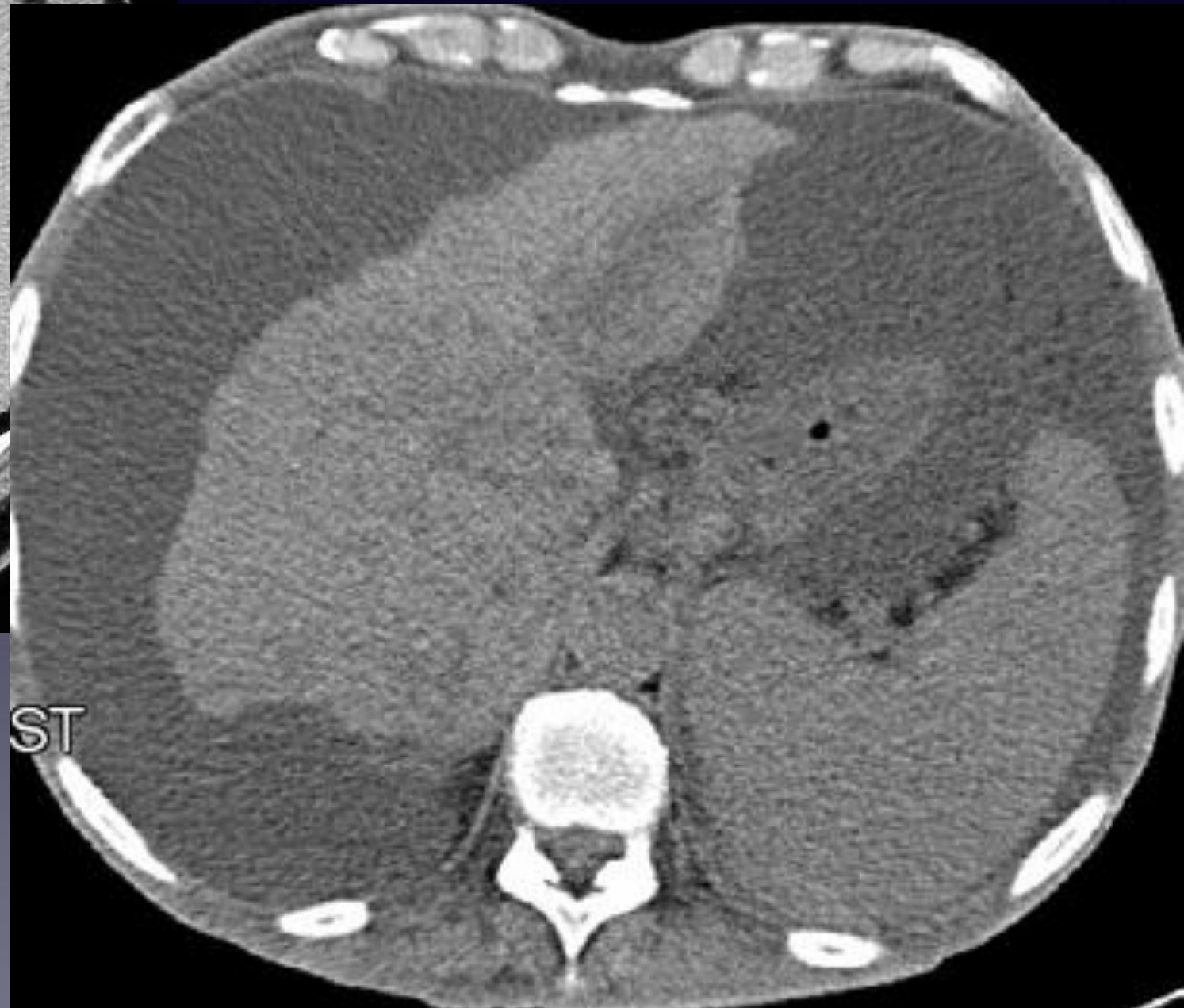
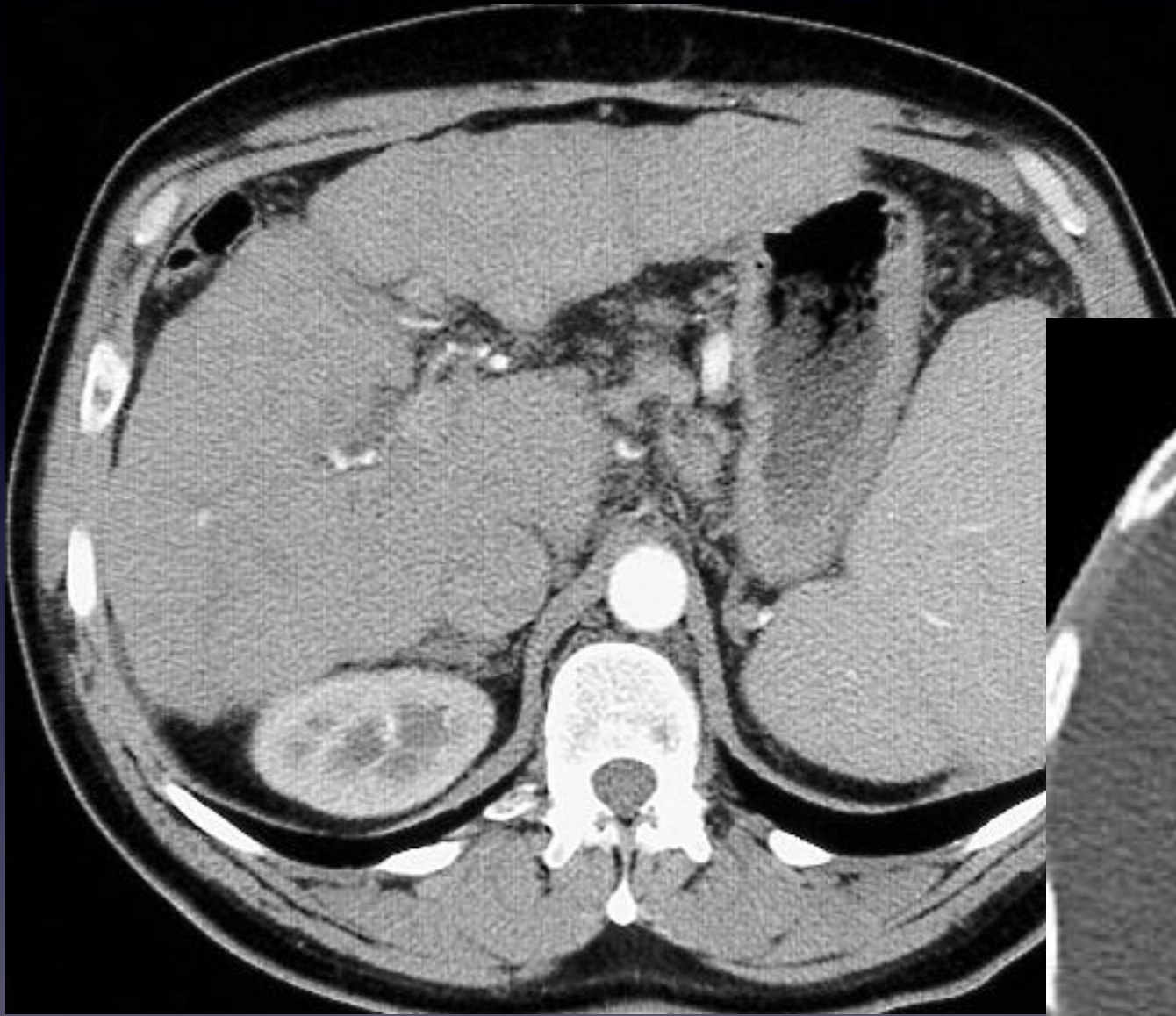
# Cirrhosis & CT-- What else can it show?

- More definitive morphologic evaluation
- Secondary signs of portal hypertension --  
Varices/splenomegally
- Ascites
- HCC



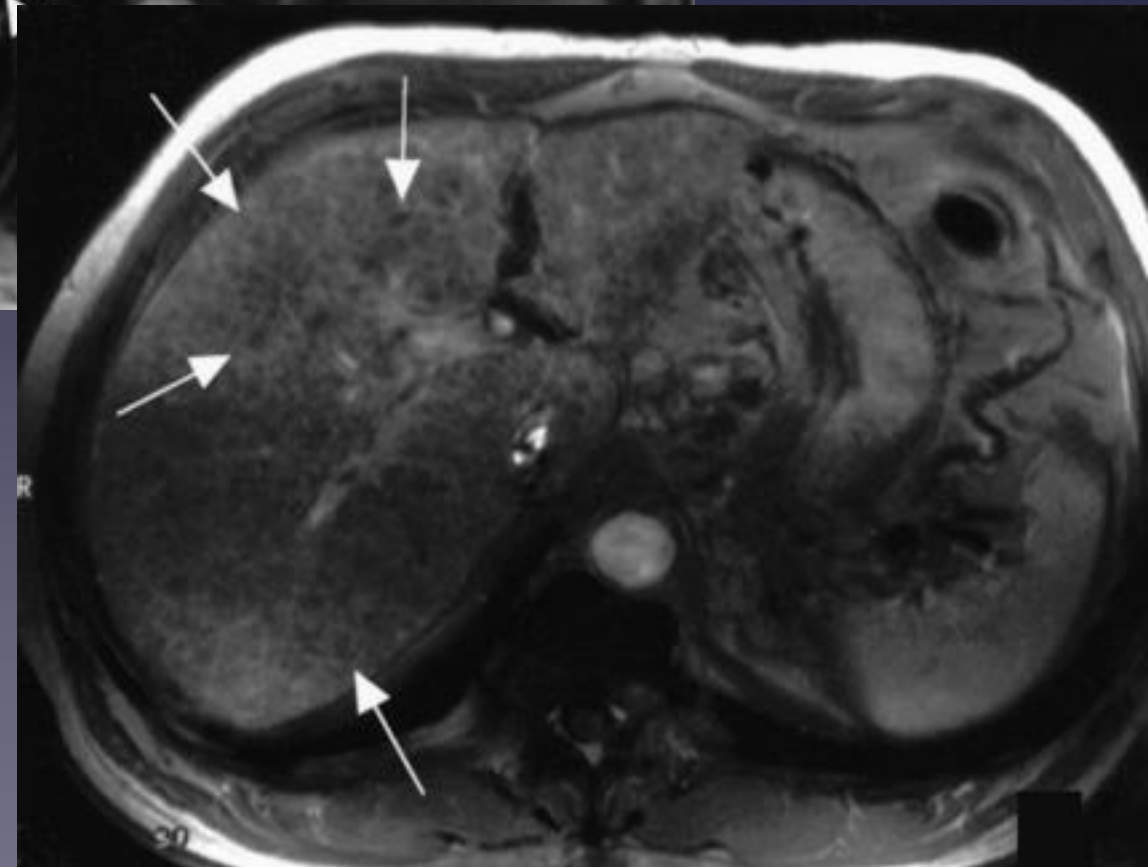
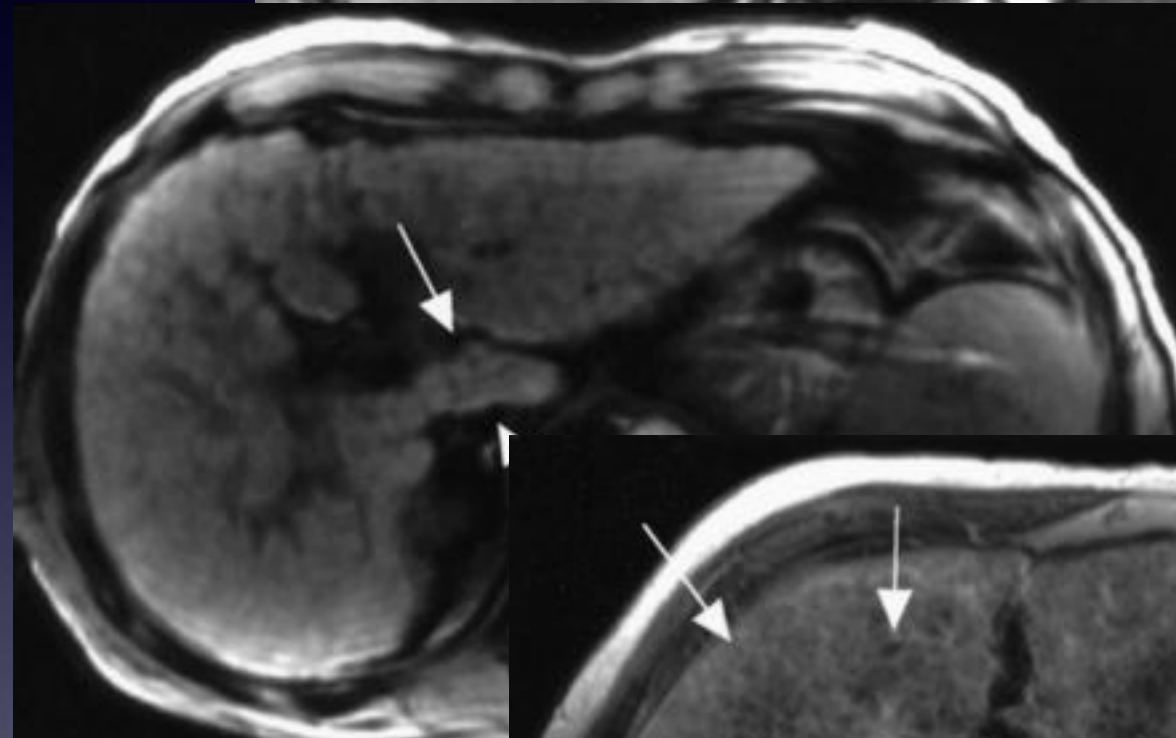
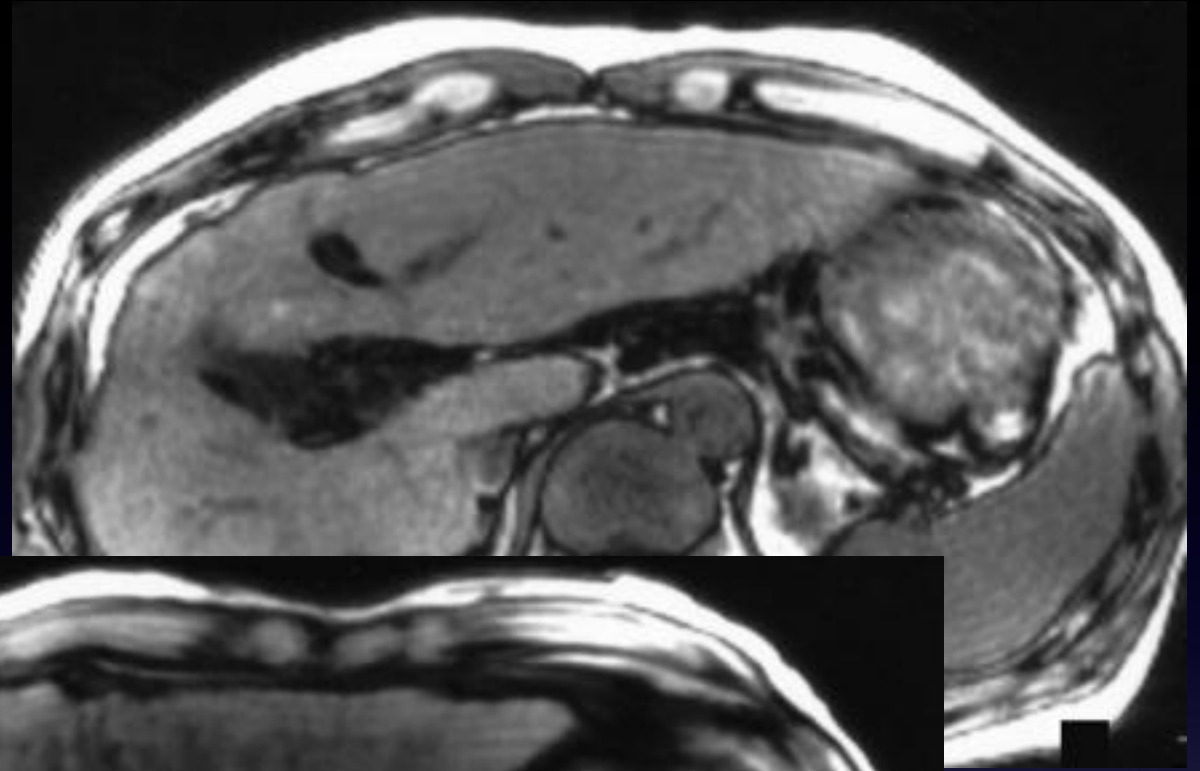
# CT appearance of cirrhosis





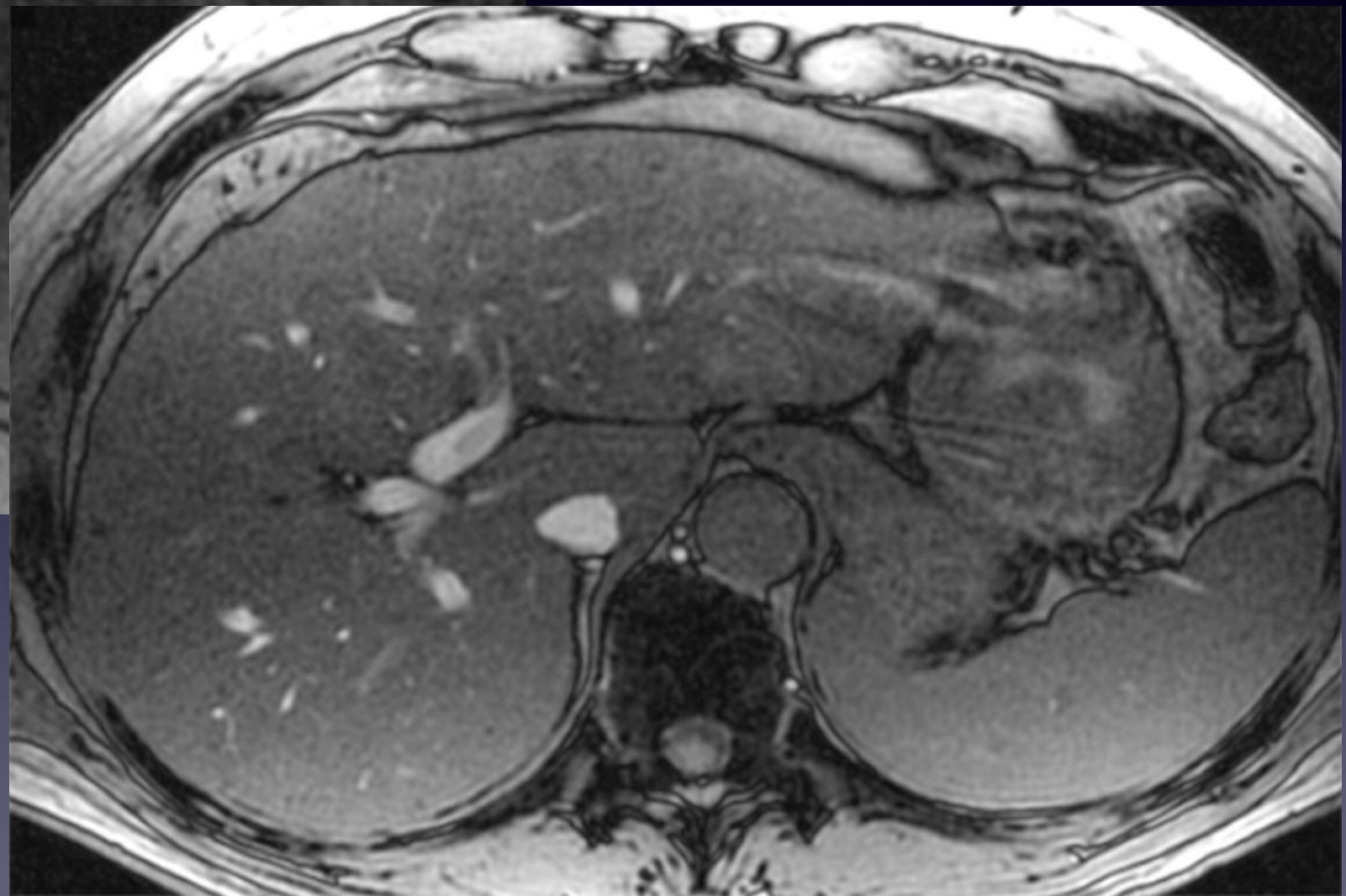
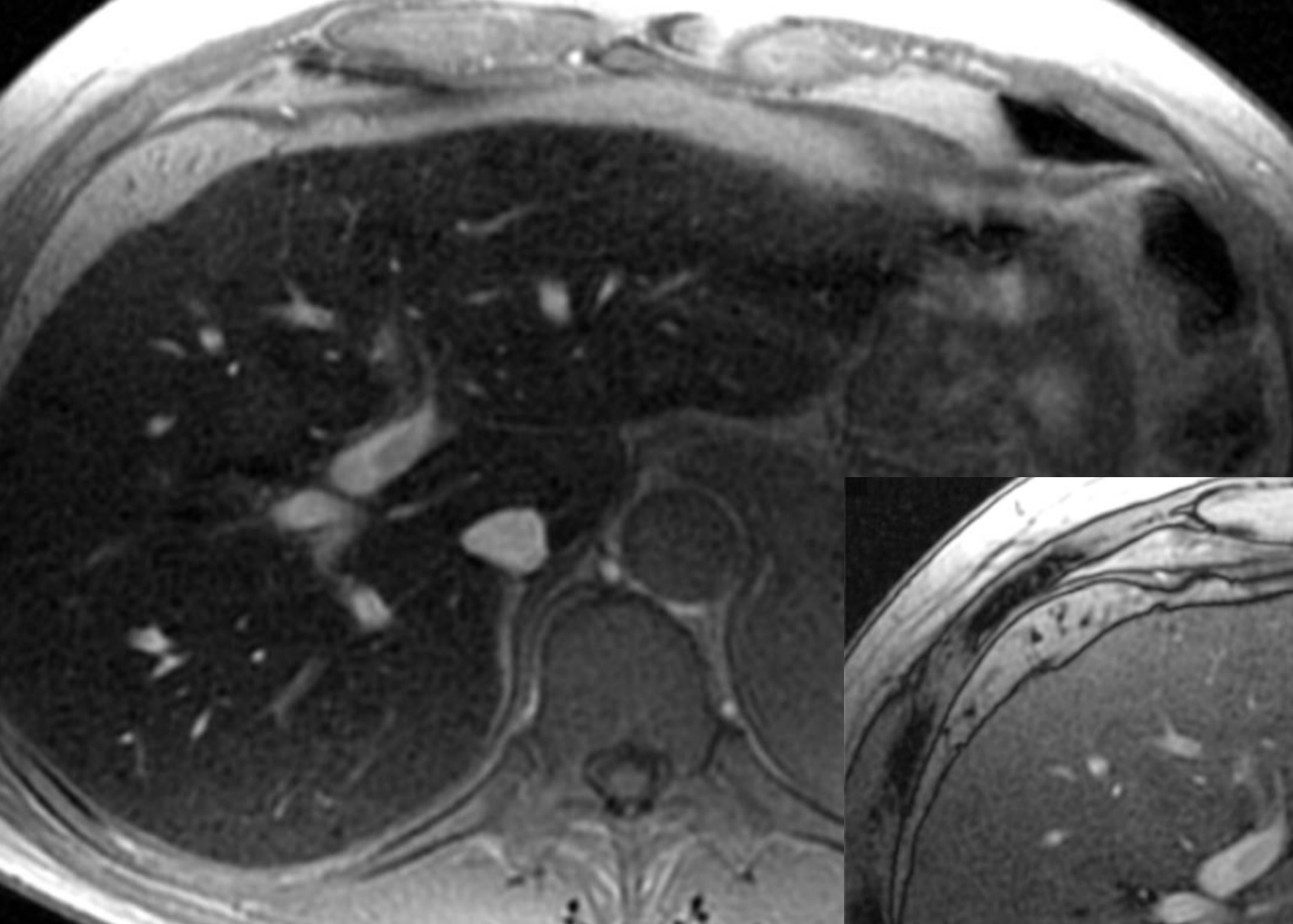
# Cirrhosis & MRI

- Most definitive Morphologic and Physiologic imaging modality
- Additional findings
  - Dysplastic nodules
  - Siderotic nodules
- Nodule within a nodule
- HCC focus within Dysplastic nodule
- DIFFUSION



# 48 year old male

- Fatigue
- Arthralgia
- Diabetes mellitus
- Elevated AST and ALT normal ALK phos
- Bronze colored skin



48 male genetic hemochromatosis  
In/opposed-phase paradoxical drop in liver  
signal from accelerated  $T2^*$  decay

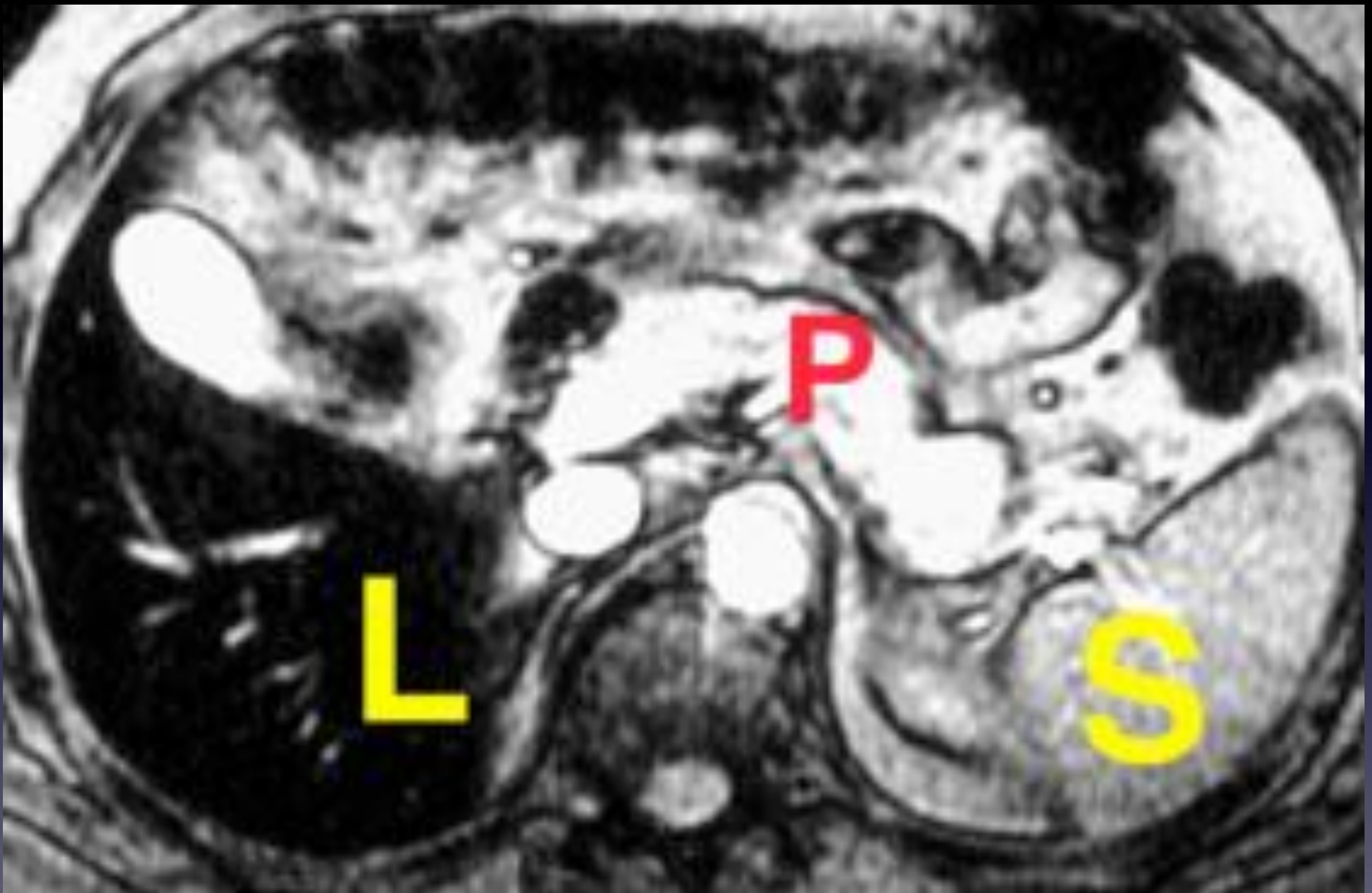

# Iron Overload-Hepatic Siderosis

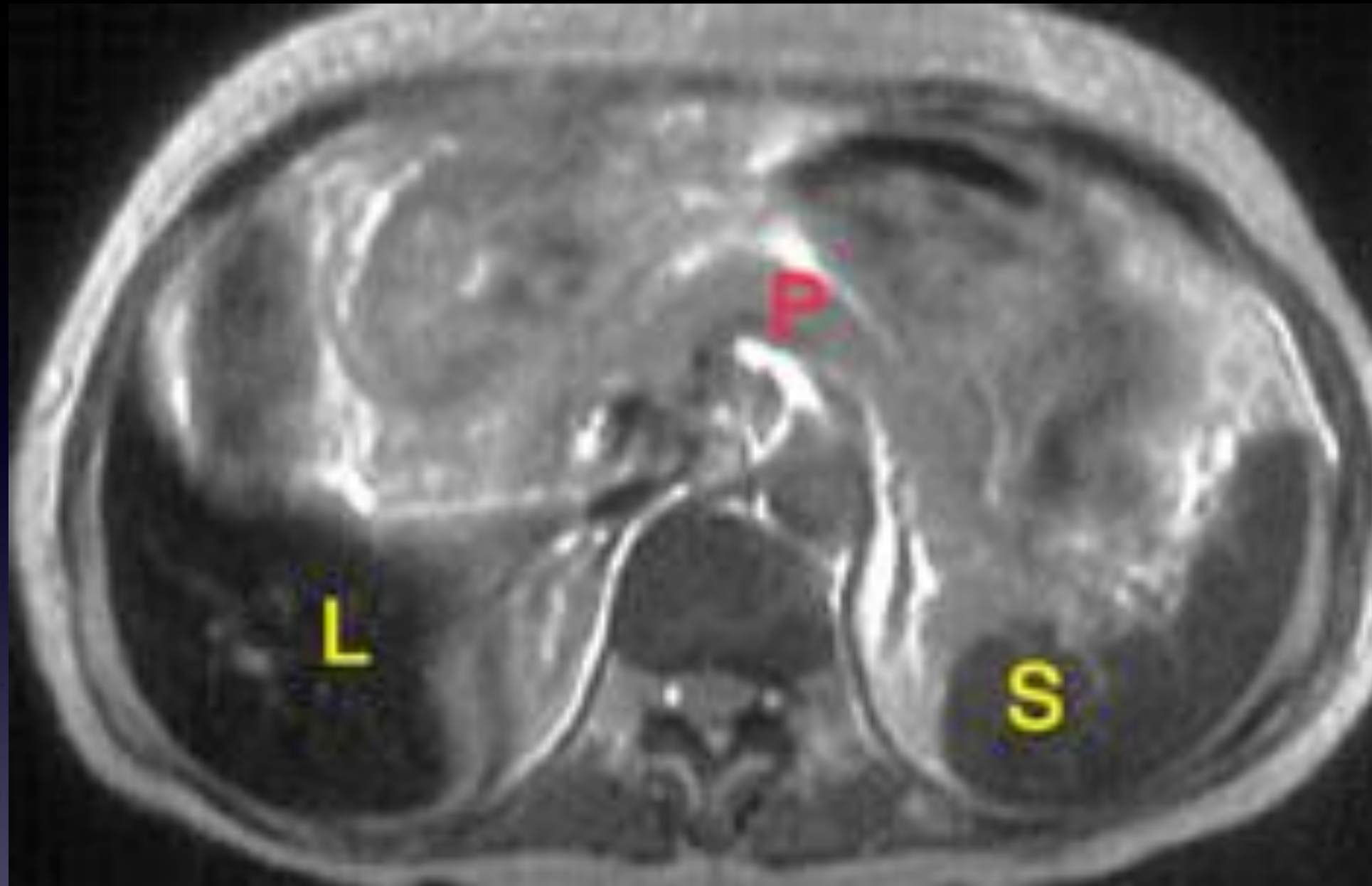
- Various causes
  - genetic hemochromatosis
  - transfusional hemosiderosis
  - chronic inflammatory state
- Increased hepatocyte iron storage
  - toxic/inflammatory response
  - leading to cirrhosis and Hepatocellular carcinoma

# Hepatic Siderosis

- Once identified biopsy is the standard of care
- Can be quantified and followed by MRI
- Conventional T2/T2\* excellent qualitative detection method
- Magnetic properties of iron, MRI is highly sensitive and specific for showing the concentration and distribution of iron

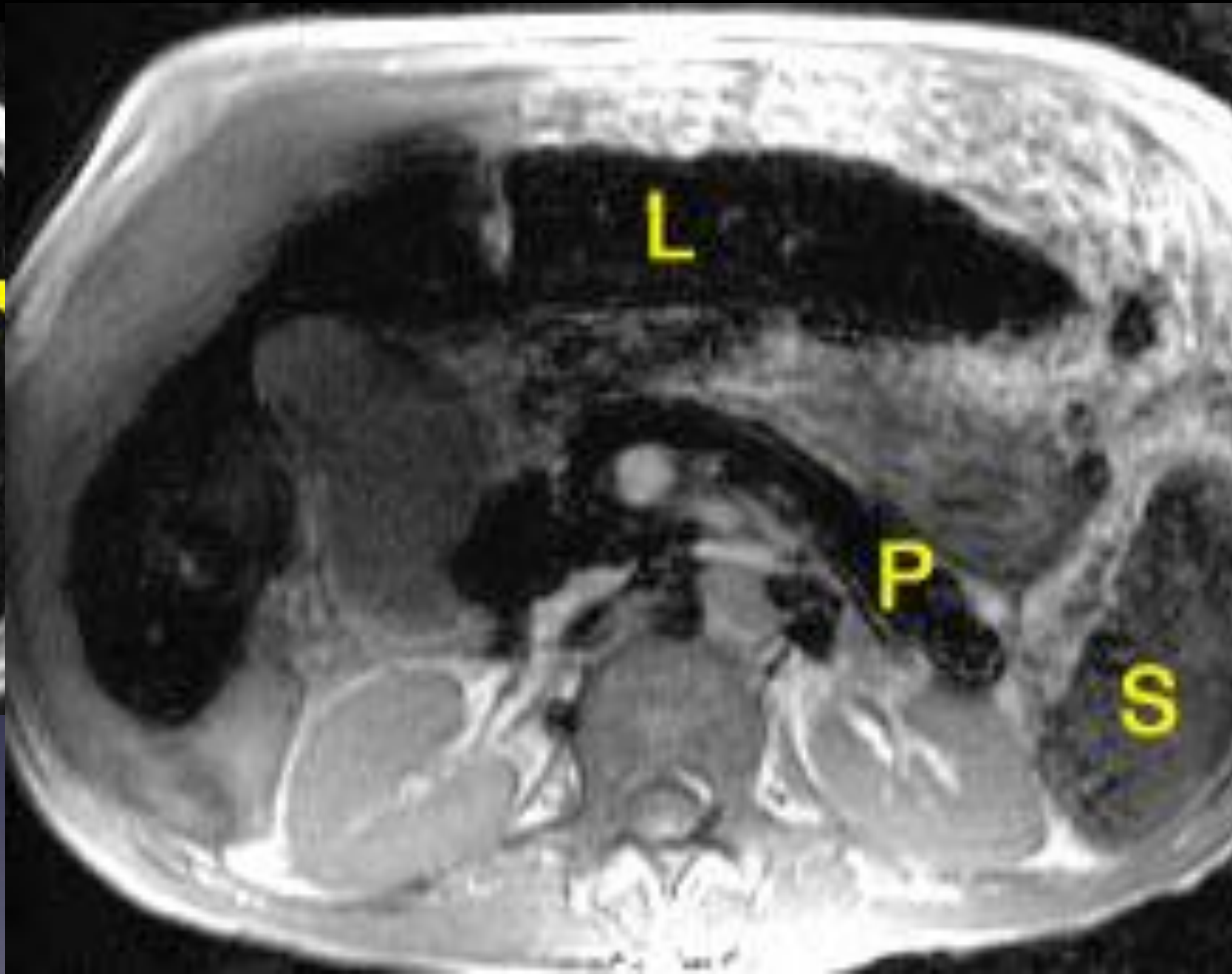
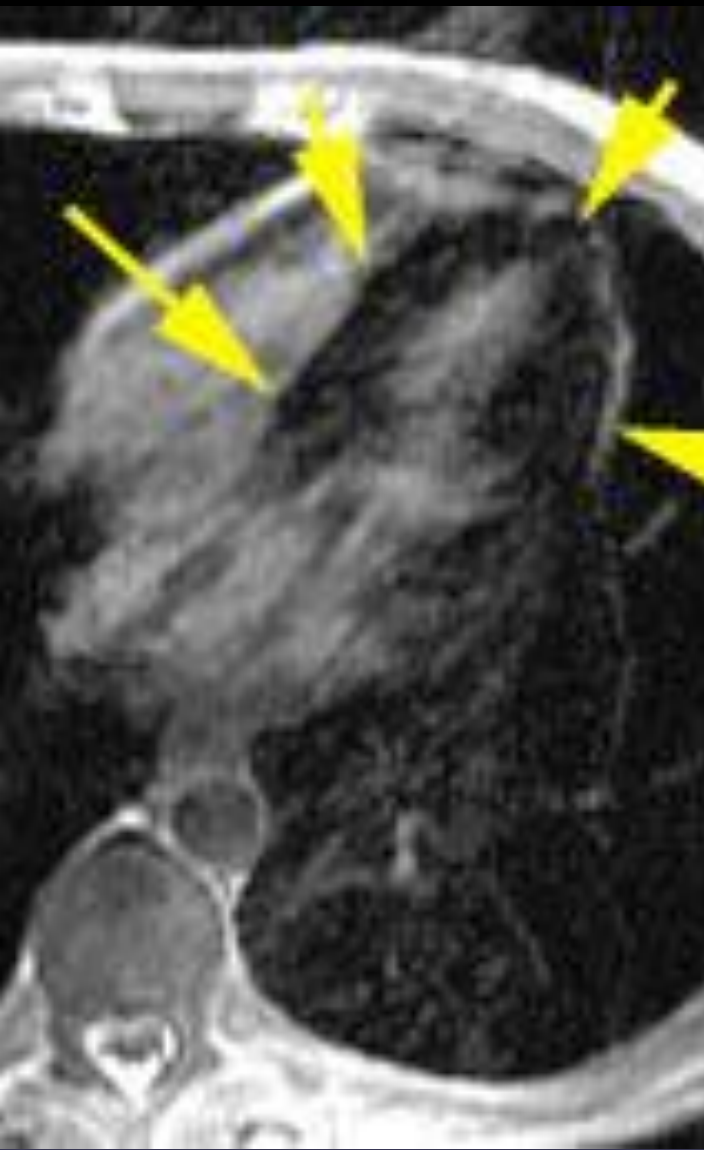


35 yo male genetic hemochromatosis note  
normal spleen



Different patient with transfusional siderosis  
note the spleen is lower in signal





Genetic hemochromatosis decreased signal of pancreas and myocardium

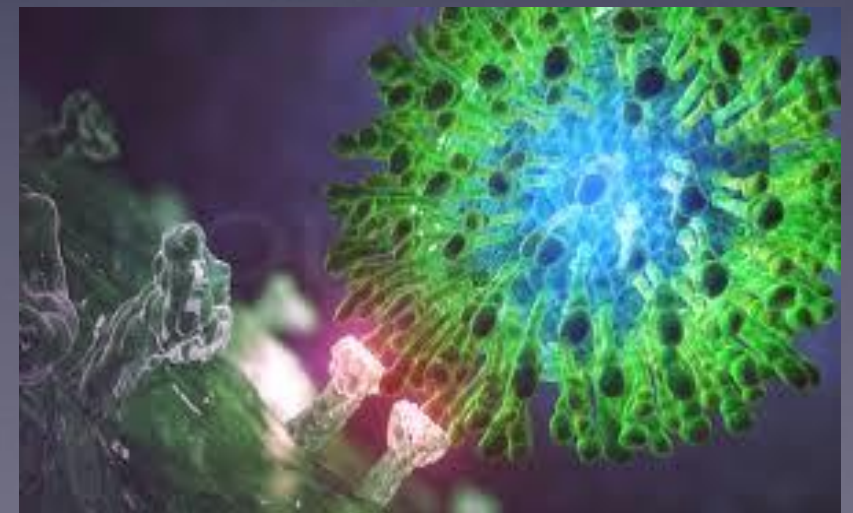
# Genetic Hemochromatosis

- These patients can have a normal life expectancy
- If the diagnosis is made early and treatment begins
- If the disease goes undiagnosed or untreated
  - significant morbidity and mortality
  - cirrhosis/HCC/death

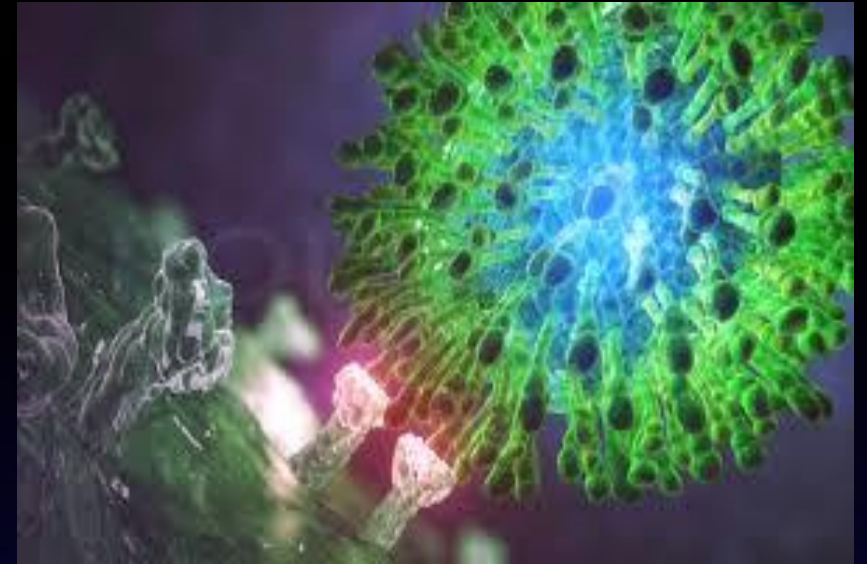


# Viral Hepatitis

- HCV
  - 170 million world wide
  - 2.7 million in the US with active HCV
  - 20% of all cases of acute hepatitis
  - 30,000 new infections per year
  - approximately 10,000 deaths per year
  - Cost of >600 million a year

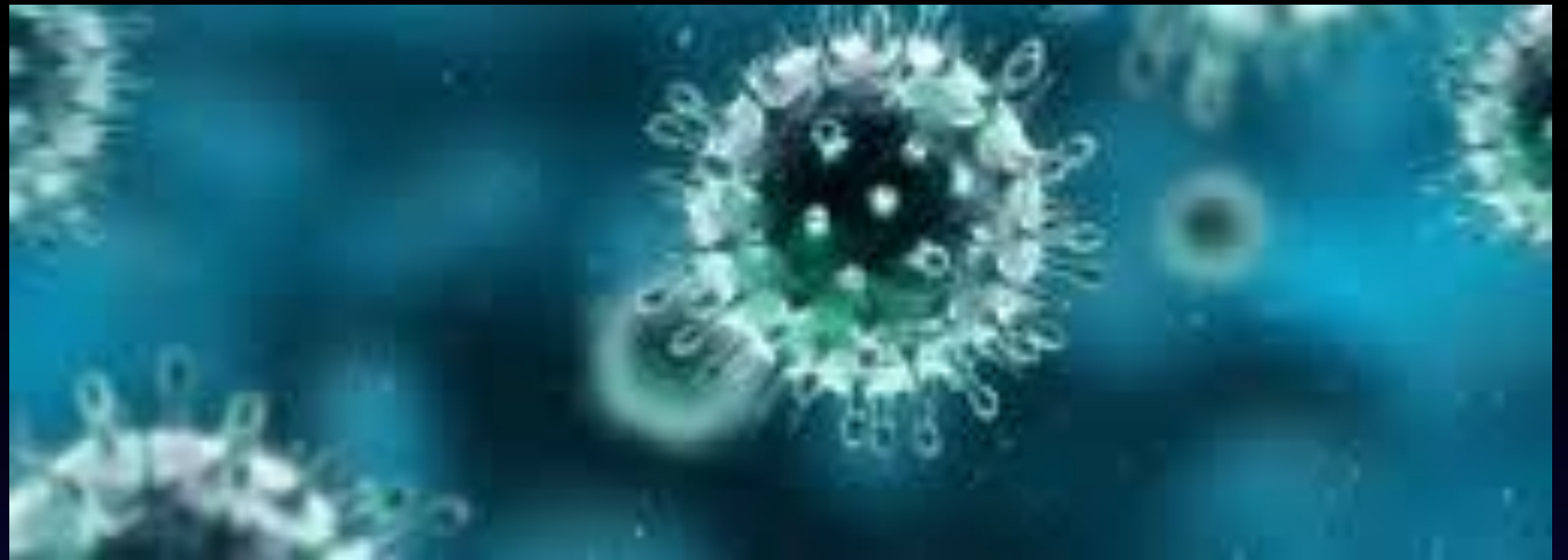

# HCV



- . Progression to cirrhosis
- . Hepatocellular carcinoma
- . Most common indication for liver transplantation

# HBV

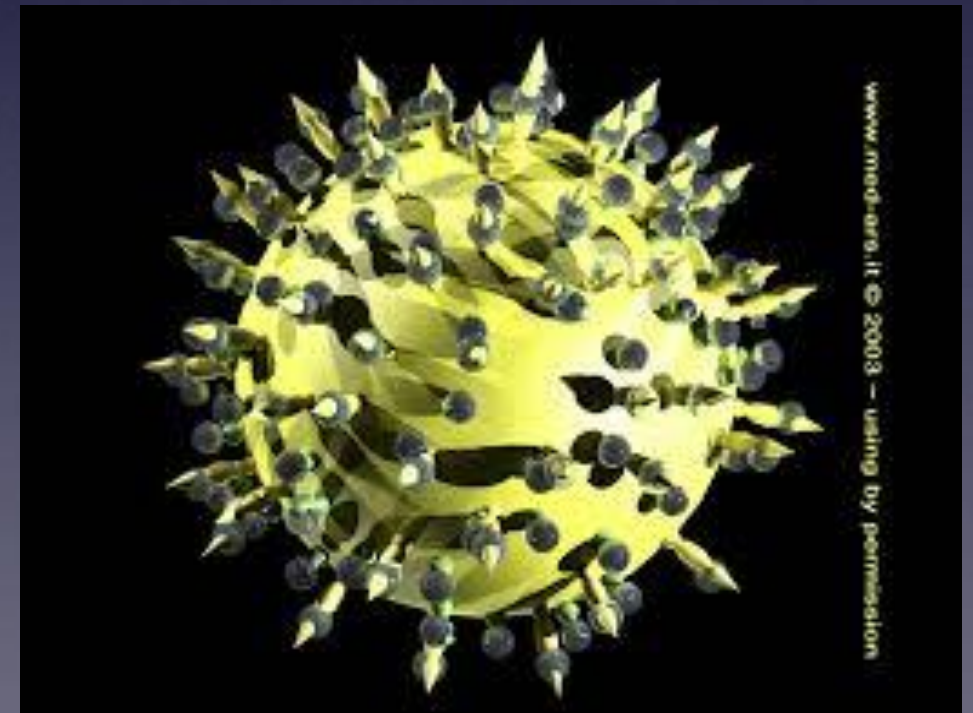


- . Worldwide epidemic
- . 1/3 of global population
- . 350 million life long carriers
- . Hematogenous and sexually transmitted

Ongoing Vaccination programs are promising

# HBV

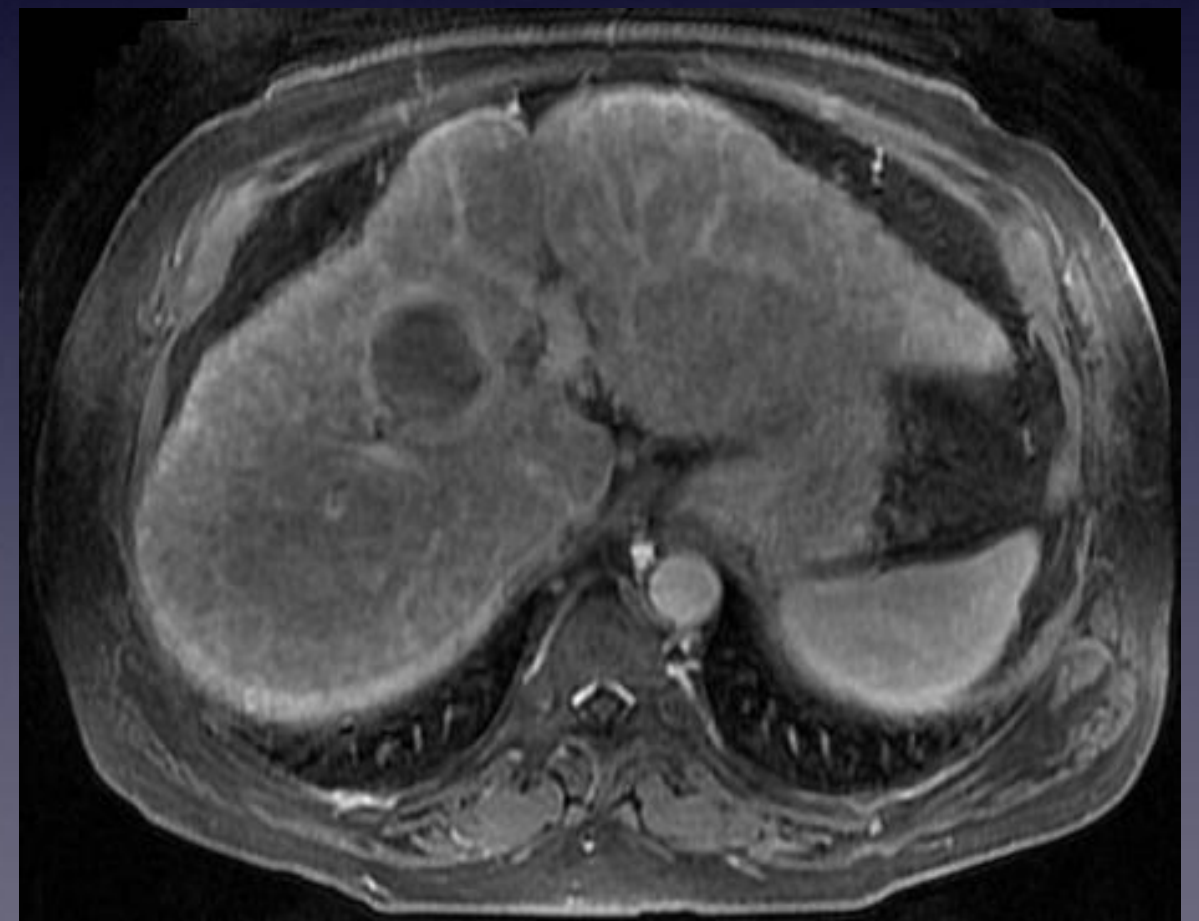
- Acute symptomatic disease
- Asymptomatic disease
- Cirrhosis
- HCC
- Liver transplant





# HCC

- Most common primary Liver cancer
- Accounting for more 500,000 deaths per year
- Most commonly seen in the setting of cirrhosis
  - Fibrolamellar HCC
  - HCV/HBV



# AASLD

## American association for the study of liver disease

- . Ultrasonography
  - . Sensitivity between 50 and 85%
  - . 90% specific when used as a screening test
- . 6 month surveillance intervals
- . Drawbacks
  - . Operator dependent
  - . Limitations from body habitus
  - . Endstage cirrhosis



# Detection of malignant tumors in end-stage cirrhotic livers: efficacy of sonography as a screening technique.

[Dodd GD 3rd](#), [Miller WJ](#), [Baron RL](#), [Skolnick ML](#), [Campbell WL](#).

## Source

Department of Radiology, Presbyterian University Hospital, Pittsburgh, PA 15213.

- Conclusion: Sonography is highly insensitive (50%) in the detection of malignant lesions in end-stage cirrhotic livers
- Not reliable for screening
- High specificity, any sonographic lesion (cirrhotic liver) should be considered malignant until proven

# Screening Recommendations for HCC

- Patients on the transplant waiting list should be screened for HCC because in the USA the development of HCC gives increased priority for OLT
- Surveillance for HCC should be performed using ultrasonography
- Patients should be screened at 6 month intervals
- The surveillance interval does not need to be shortened for patients at higher risk of HCC

Groups for whom HCC surveillance is recommended or in whom the risk of HCC is increased, but in whom efficacy of surveillance has not been demonstrated

Asian male hepatitis B carriers over age 40 0.2 0.4-0.6%/year

Asian female hepatitis B carriers over age 50 0.2 0.3-0.6%/year

Hepatitis B carrier with family history of HCC 0.2 Incidence higher than without family history

African/North American Blacks with hepatitis B 0.2 HCC occurs at a younger age

Cirrhotic hepatitis B carriers 0.2-1.5 3-8%/yr

Hepatitis C cirrhosis 1.5 3-5%/yr

Stage 4 primary biliary cirrhosis 1.5 3-5%/yr

Genetic hemochromatosis and cirrhosis 1.5 Unknown, but probably > 1.5%/year

Alpha 1-antitrypsin deficiency and cirrhosis 1.5 Unknown, but probably > 1.5%/year

Other cirrhosis 1.5 Unknown

Surveillance benefit uncertain

Hepatitis B carriers younger than 40 (males) or 50 (females) 0.2 < 0.2%/yr

Hepatitis C and stage 3 fibrosis 1.5 < 1.5%/yr

Non-cirrhotic NAFLD 1.5 < 1.5%/yr

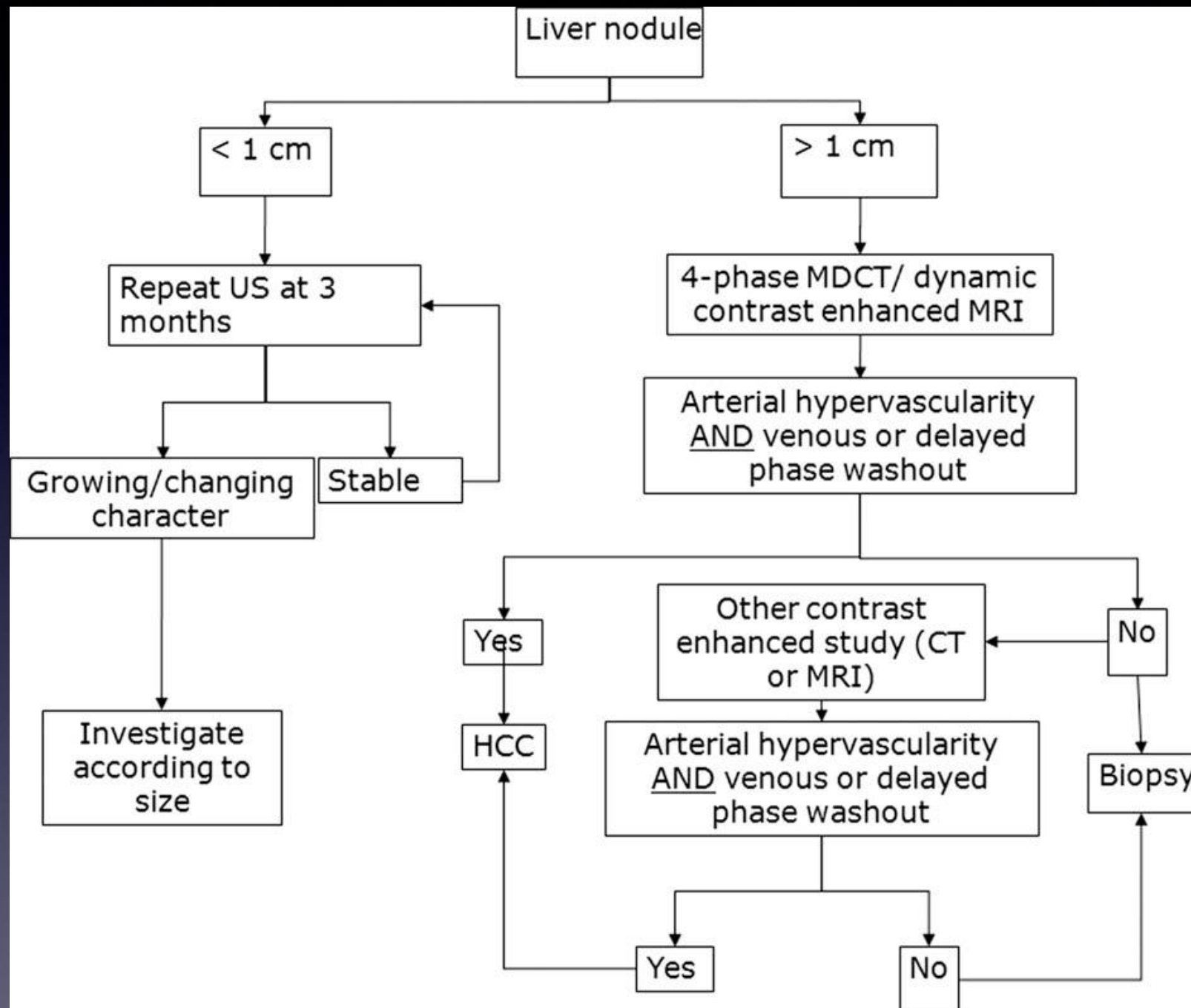
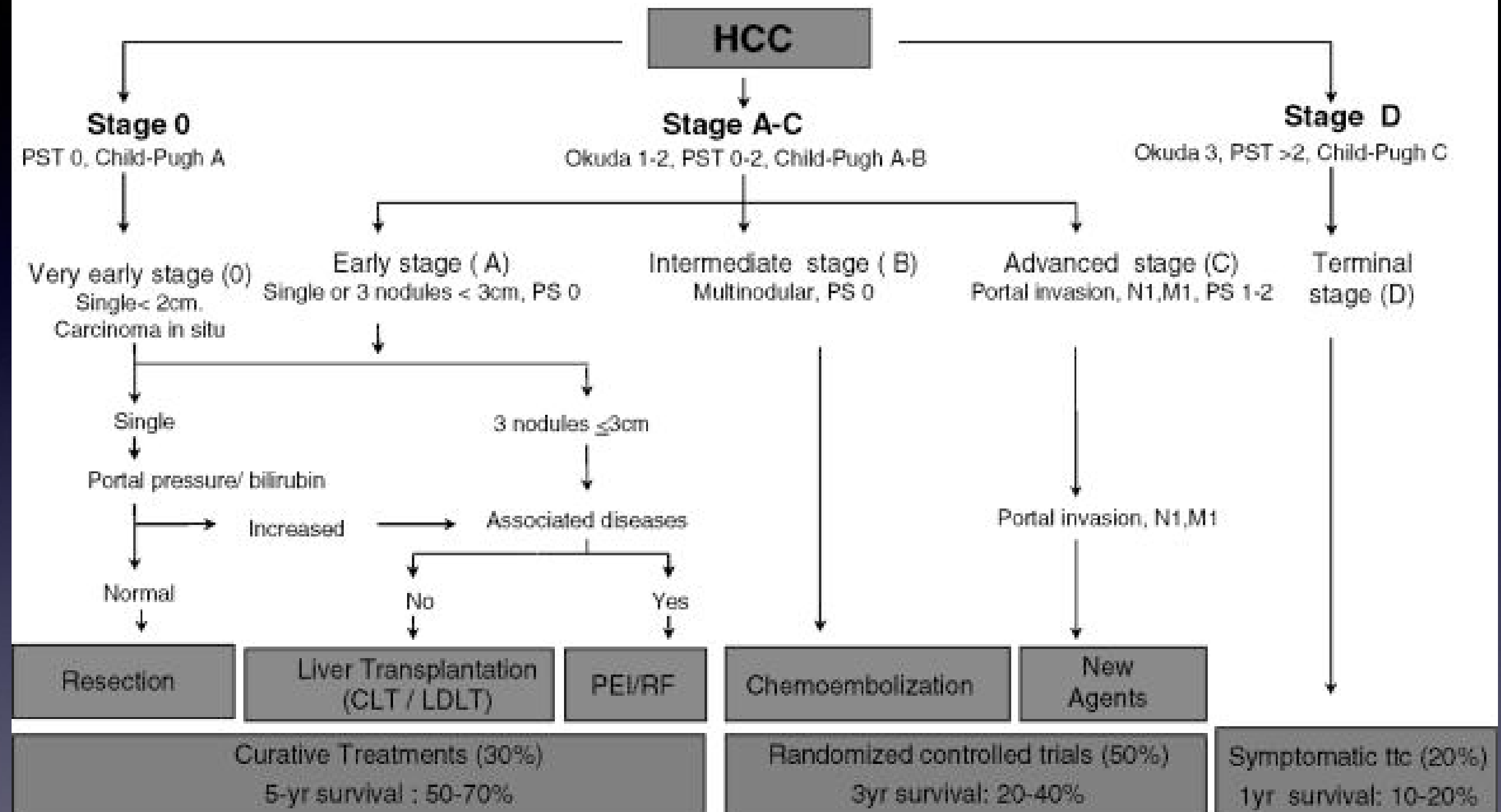
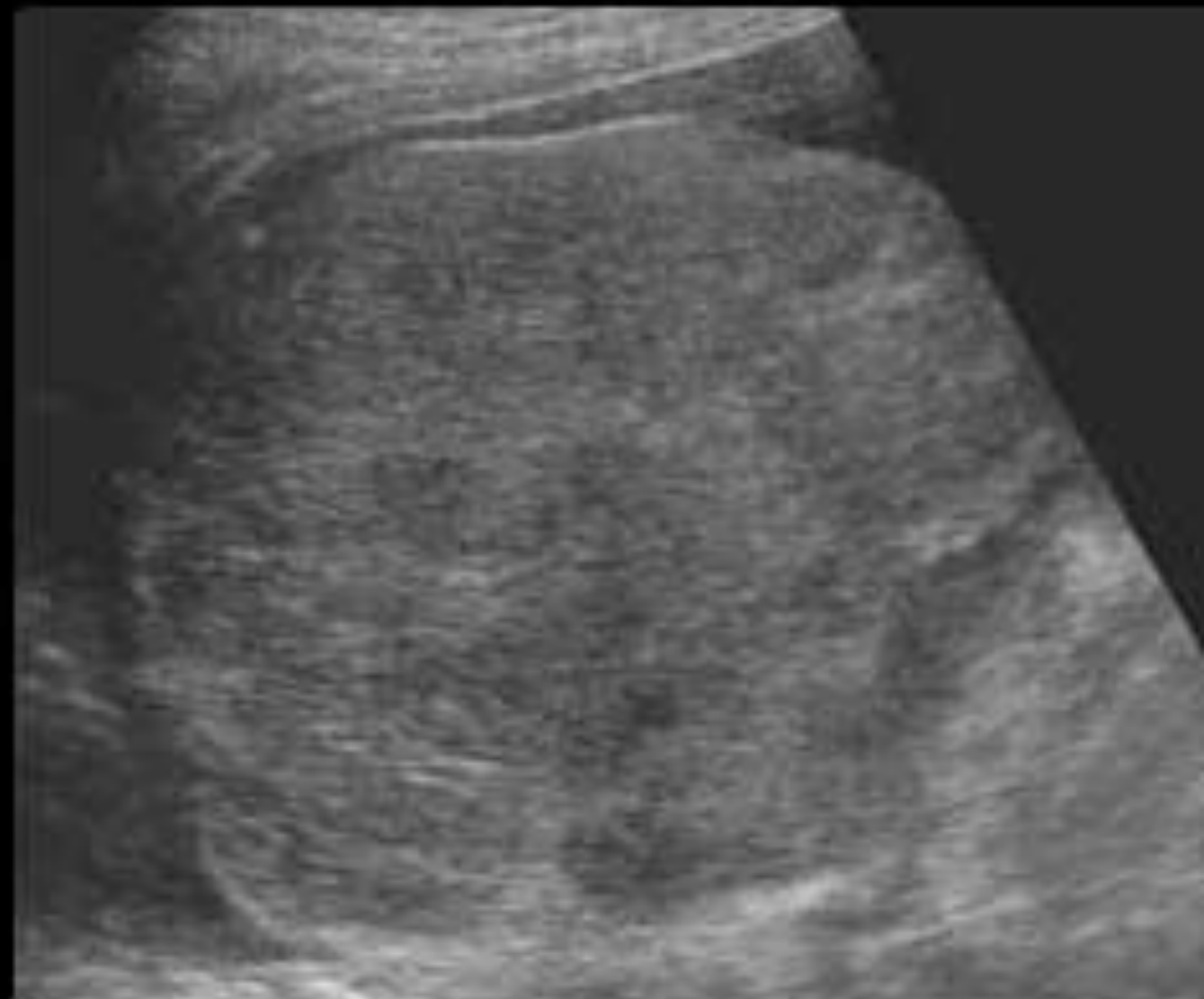
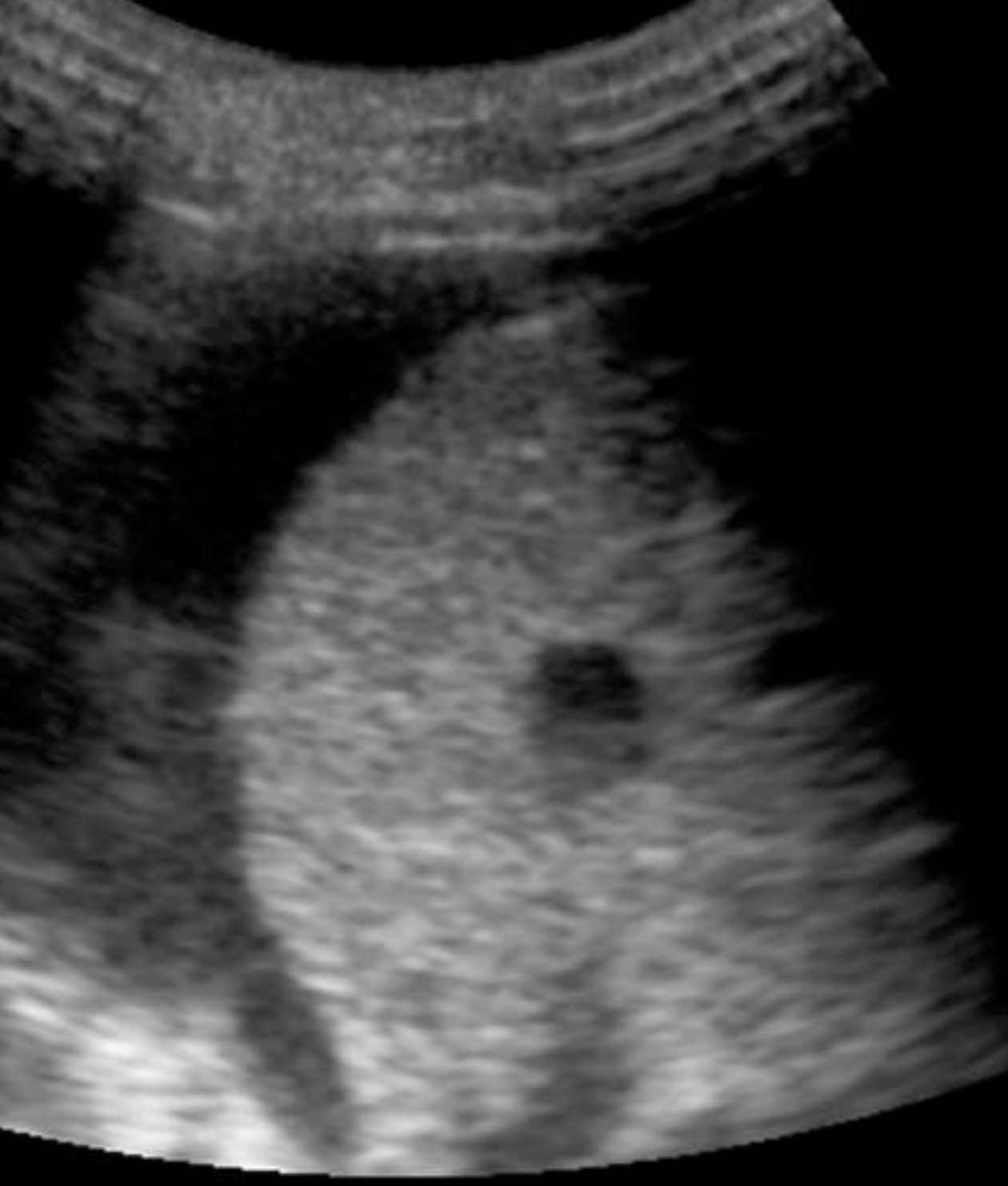
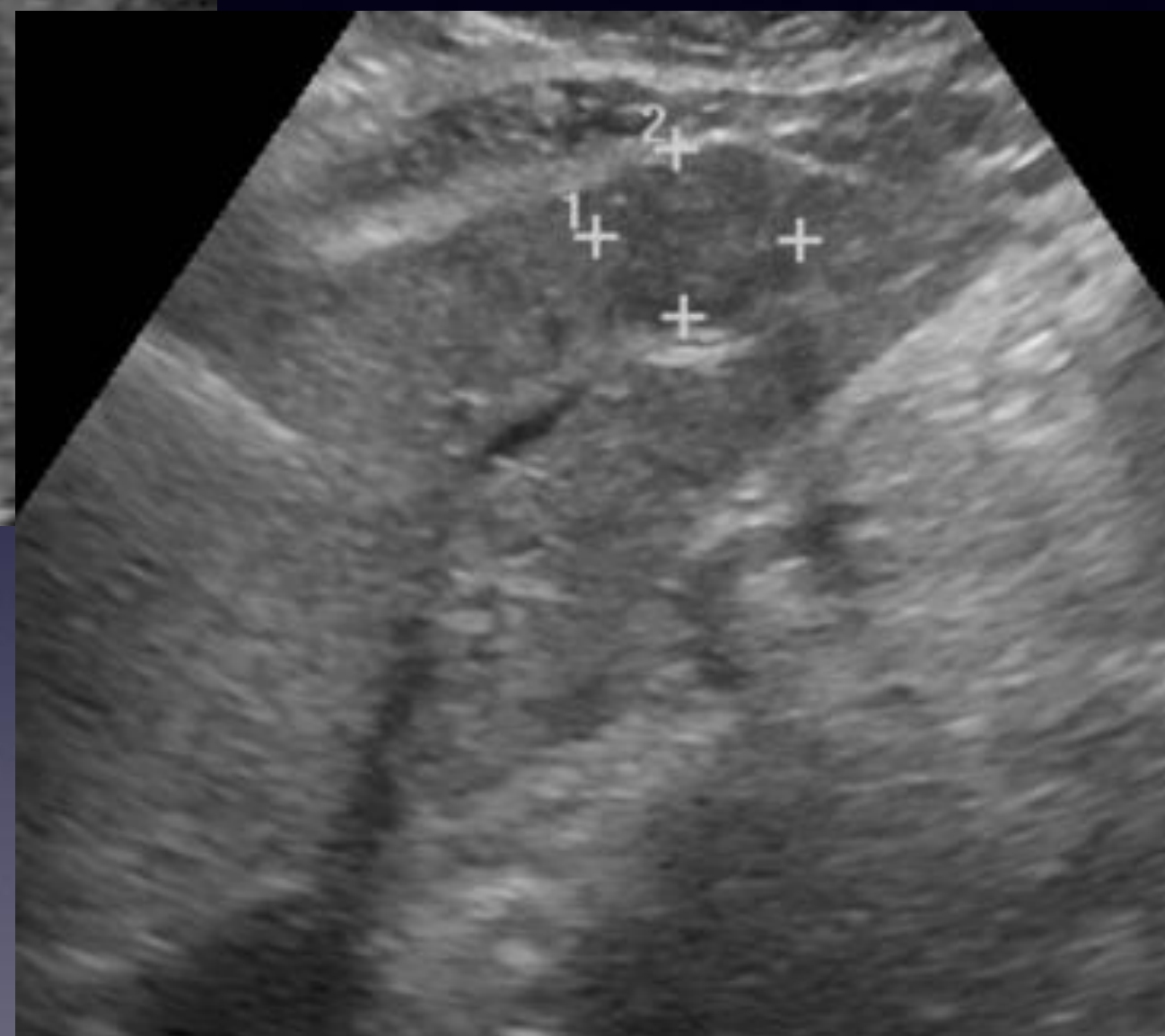
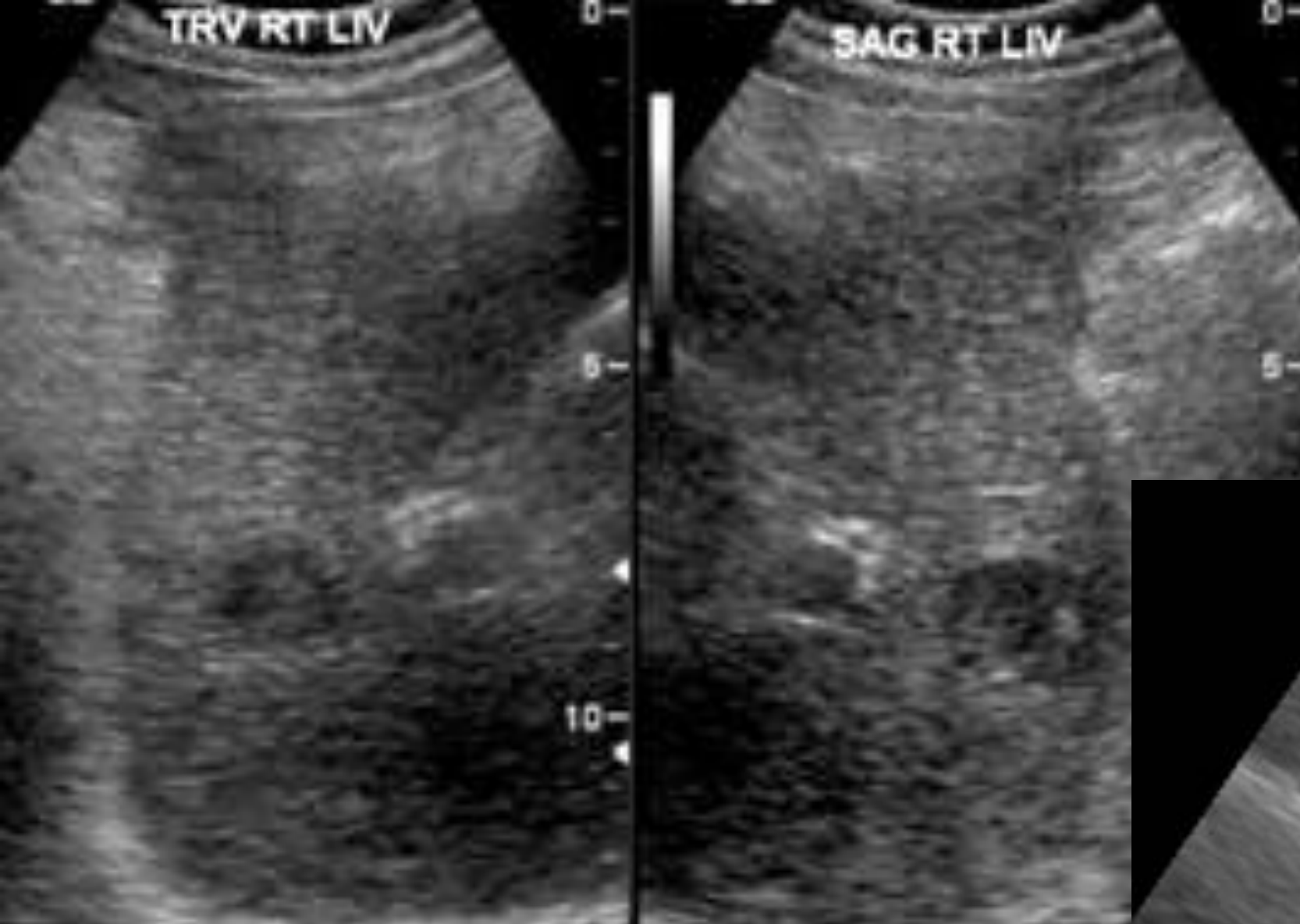Figure 1. Diagnostic algorithm for suspected HCC. CT, computed tomography; MDCT, multidetector CT; MRI, magnetic resonance imaging; US, ultrasound.

# BCLC Staging and treatment schedule

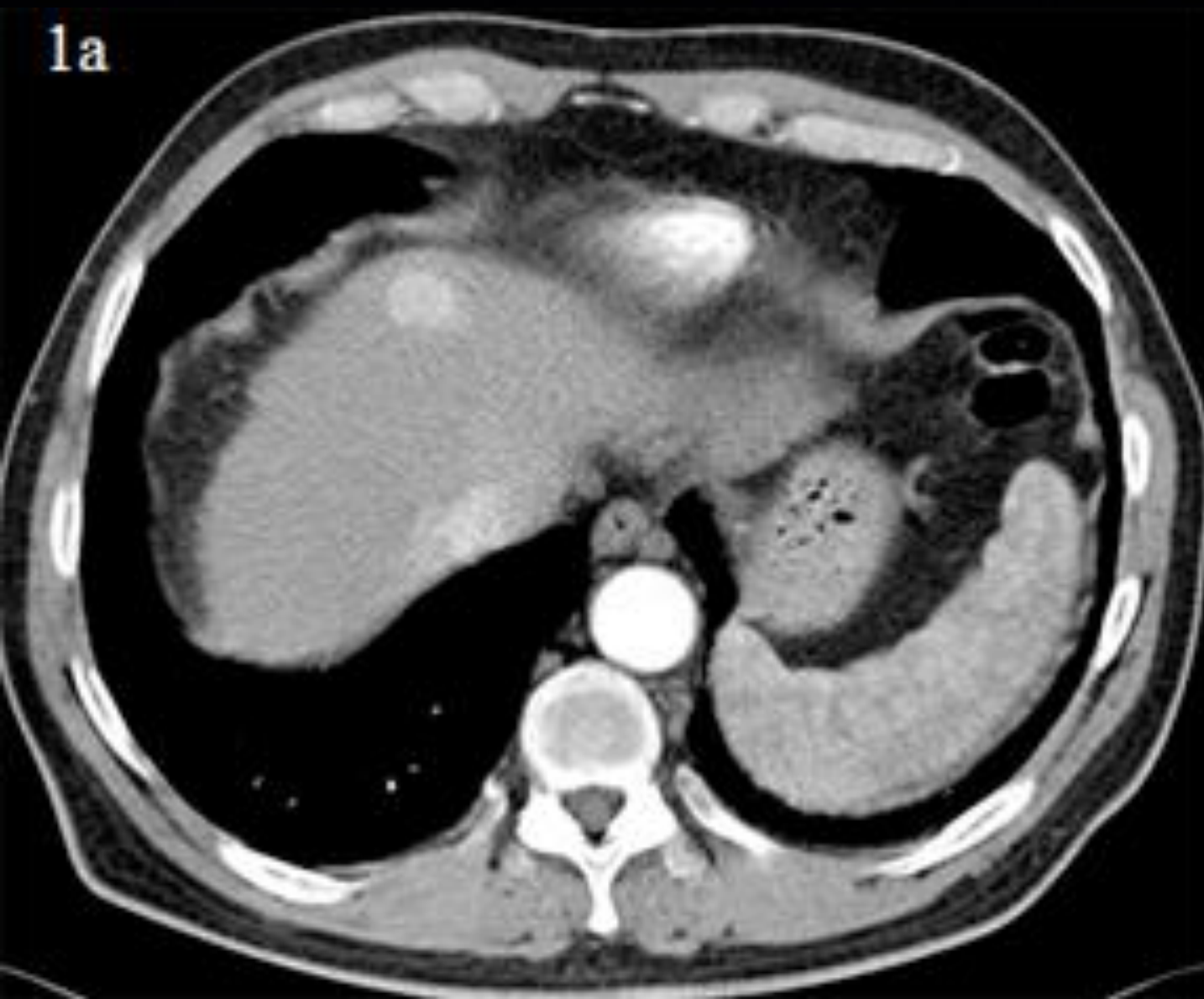




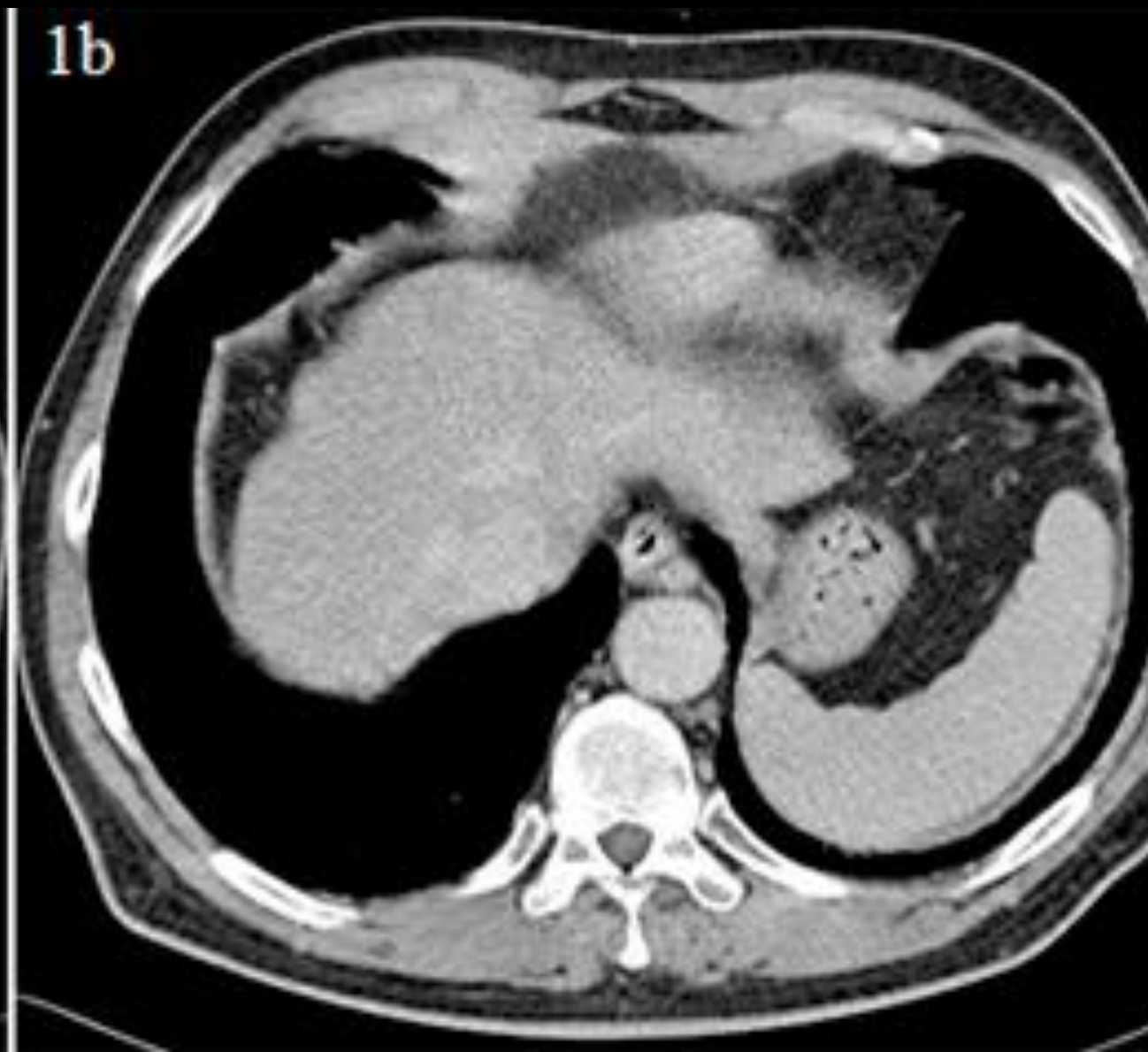


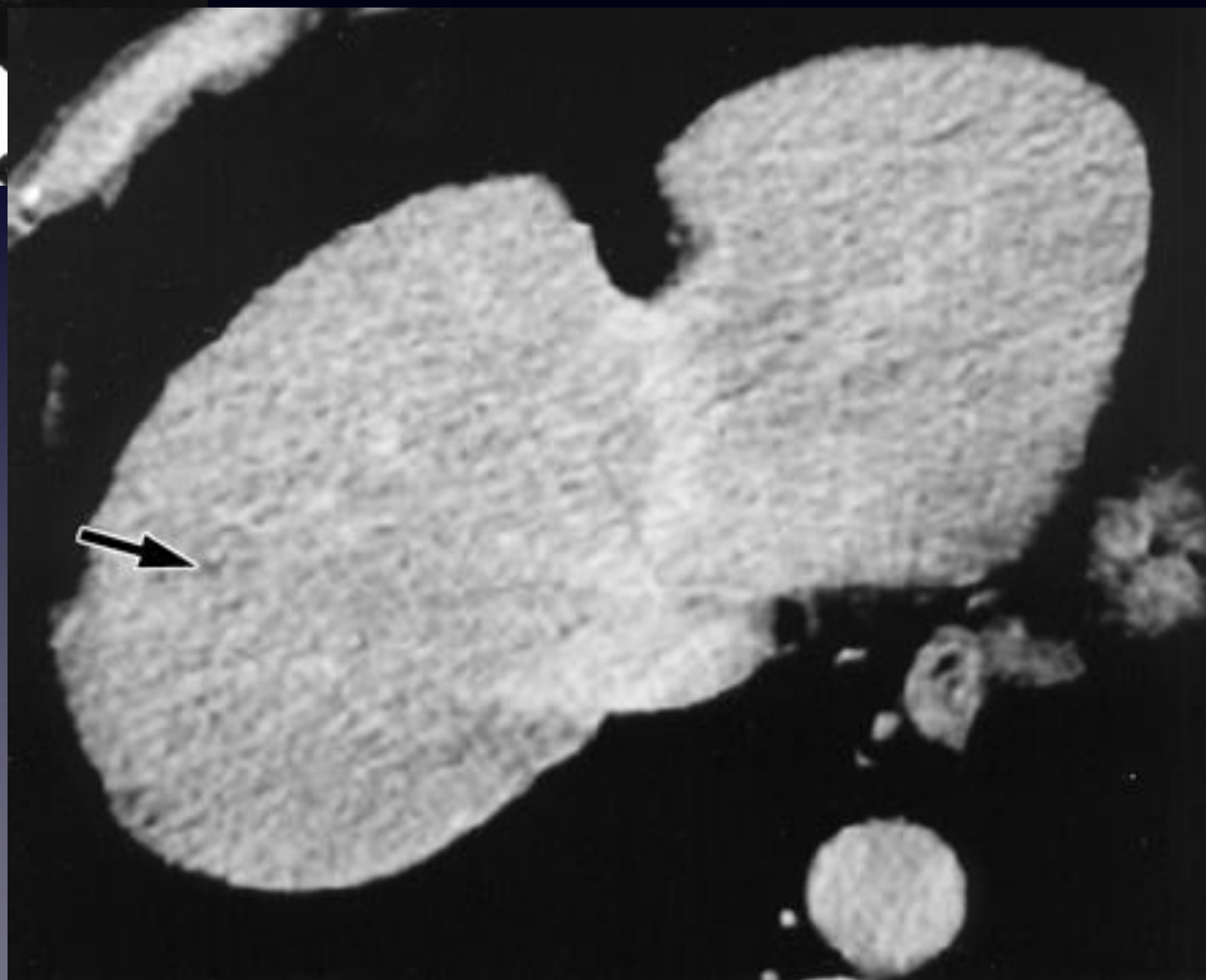
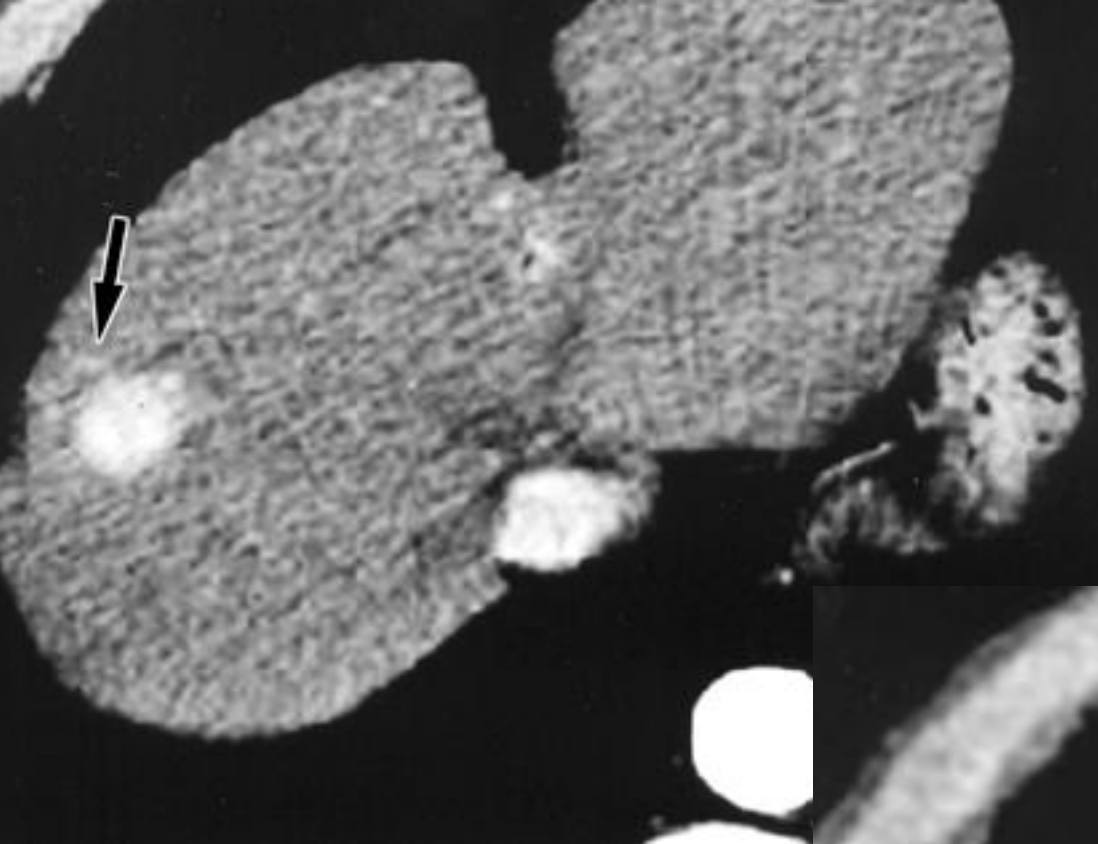


1a

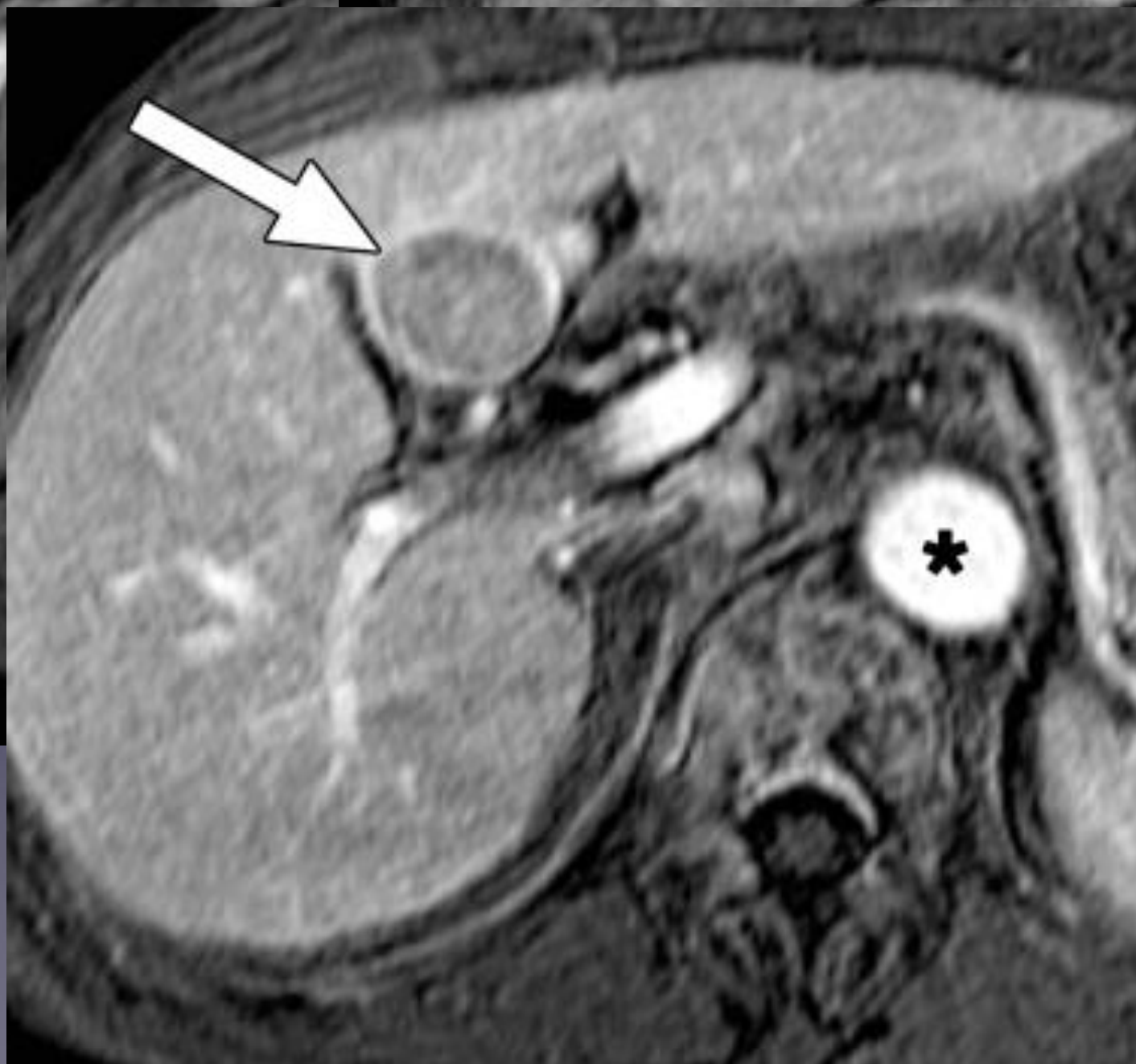
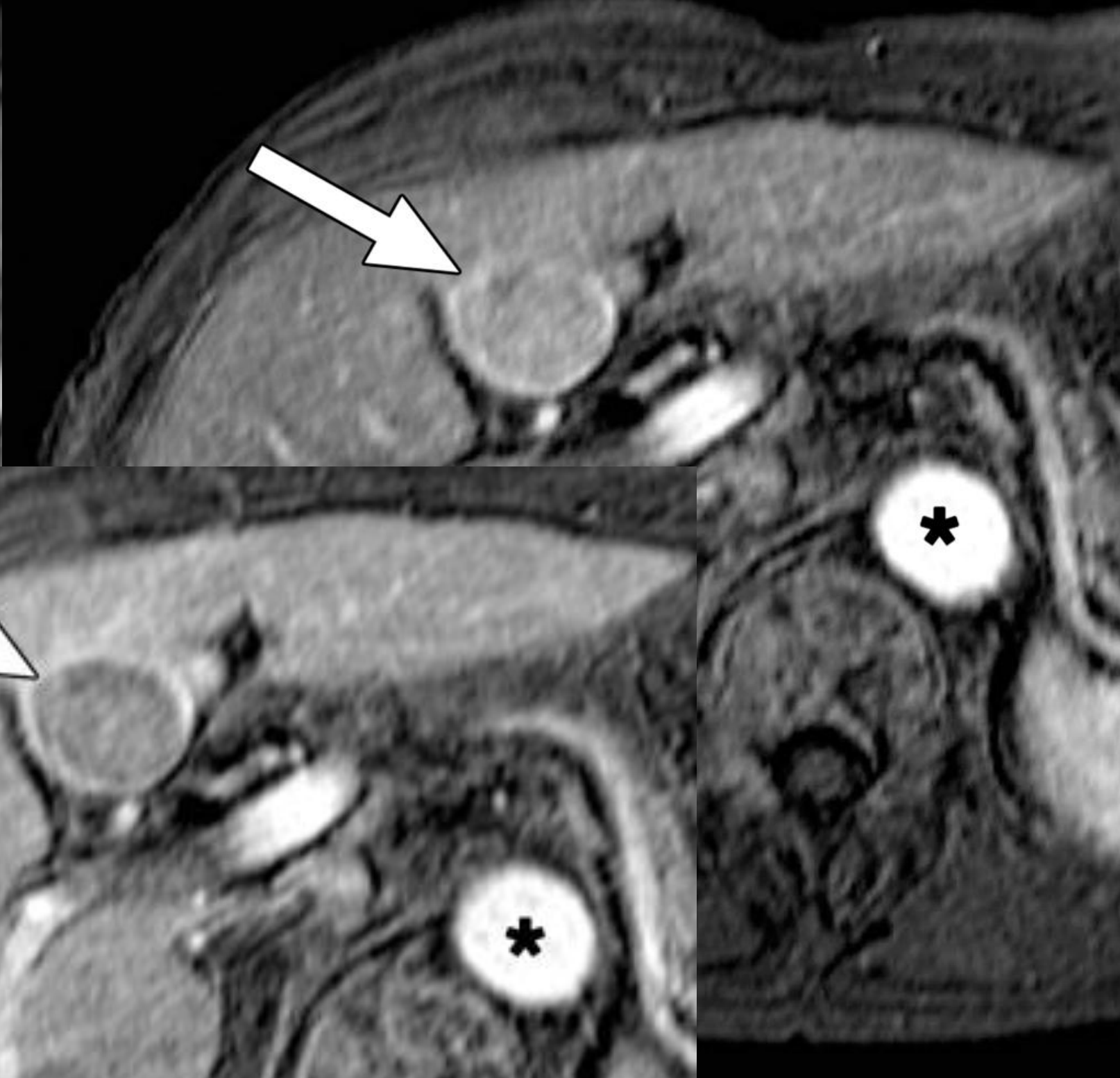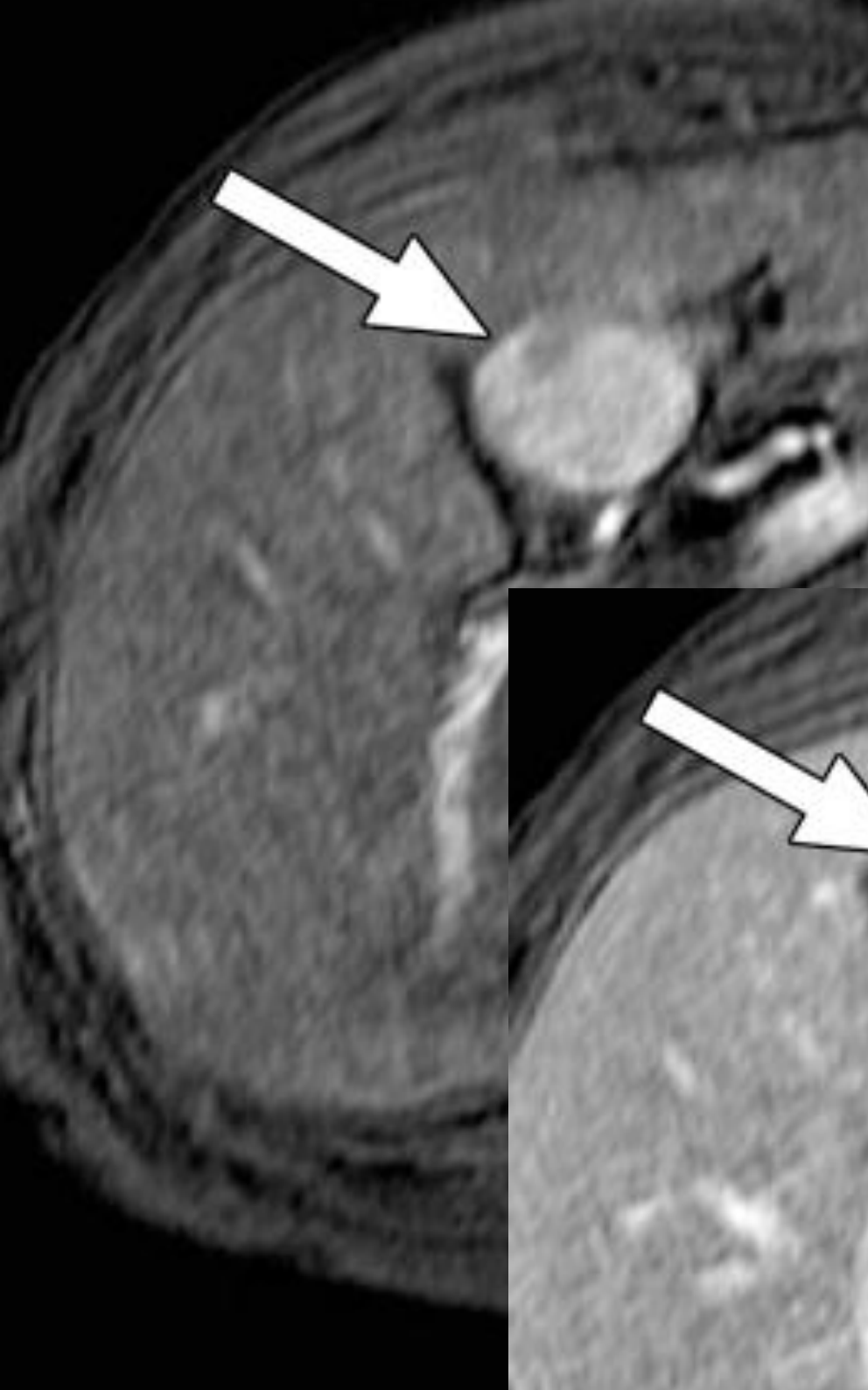


1b









# ACR Liver Imaging Reporting and Data System..... LIRADS

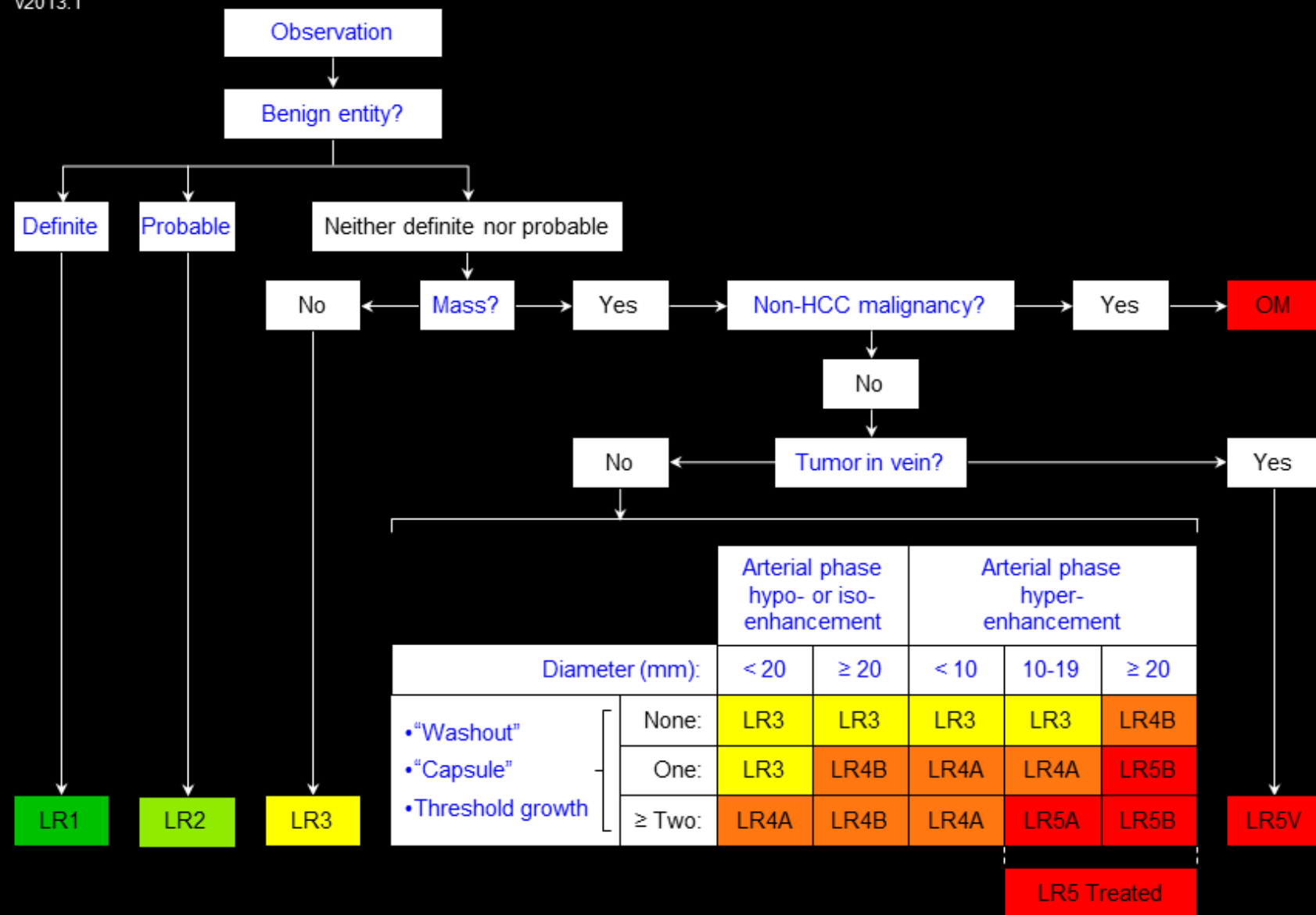
- Created to standardize reporting and data collection
  - CT and MRI
- Categorizes liver findings for patients with cirrhosis or other risk factors for developing HCC
  - Consistent terminology
- Reduce imaging interpretation variability and errors
- Enhance communication with referring clinicians
- Facilitate quality assurance and research



# ACR Liver Imaging Reporting and Data System..... LIRADS

LI-RADS   
v2013.1

[Intro](#) [Overview](#) [Categories](#) [Reporting](#) [Management](#) [Technique](#) [Index](#)



← Apply Ancillary Features and then Tie-Breaking Rules to Adjust Category →

# LIRADS 1:DEFINITELY BENIGN

- **CONCEPT**

- 100% CERTAINTY OBSERVATION IS BENIGN

- **DEFINITION**

- IMAGING FEATURE DIAGNOSTIC OF A BENIGN ENTITY
- OR DEFINITE SPONTANEOUS DISAPPEARANCE AT FOLLOW UP

# LIRADS 2: PROBABLY BENIGN

- **CONCEPT**
  - HIGH LIKELIHOOD IS BENIGN
- **DEFINITION**
  - OBSERVATION WITH IMAGING FEATURES SUGGESTIVE BUT NOT DIAGNOSTIC OF BENIGN ENTITY

# LIRADS 3: INTERMEDIATE

- NOT DEFINITE BENIGN NOT PROBABLE BENIGN ENTITY  
NOT NON-HCC MALIGNANCY AND ONE OF THE FOLLOWING
  - NOT DEFINITE MASS
  - MASS WITH HEPATIC HYPER ARTERIAL ENHANCEMENT
    - <20 MM MASS WITH NONE OF THE FOLLOWING:  
(WASHOU/CAPSULE/GROWTH)
    - >20 MM MASS WITH NONE OF THE FOLLOWING:  
(WASHOU/CAPSULE/GROWTH)

# LIRADS 4: PROBABLE HCC

## CRITERIA

- NOT DEFINITELY BENIGN ENTITY, NOT PROBABLE BENIGN ENTITY, NOT NON-HCC MALIG AND:
  - LR4A (<20 MM MASS)
    - MASS WITH HEPATIC ARTERIAL PHASE HYO OR ISO ENHANCEMENT AND  $\geq$  of the following: washout, capsule, growth
    - Mass with hyper arterial phase enhancement
    - < 10mm mass with  $\geq 2$  of following: washout, capsule, growth
    - 10-19mm mass with only 1 of following: washout, capsule growth

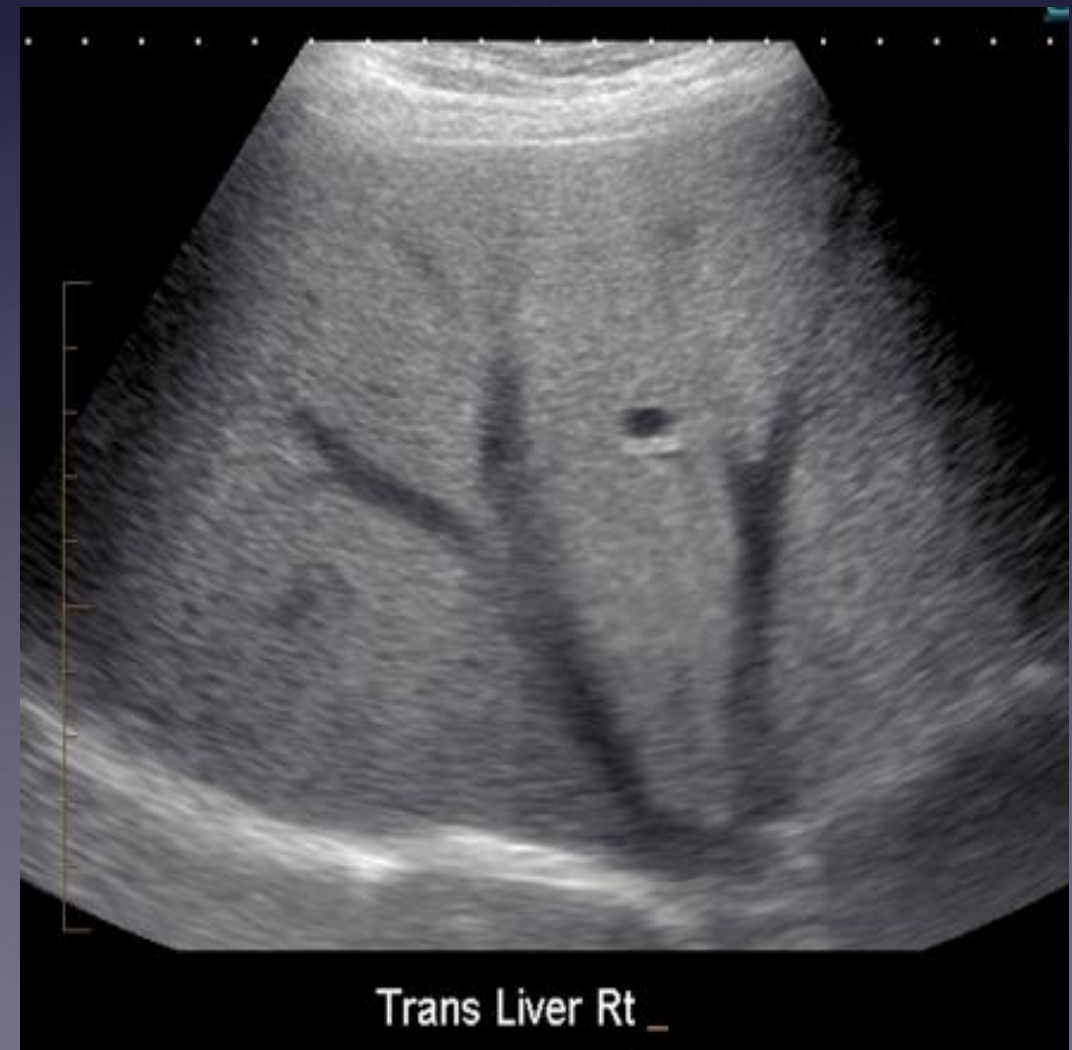

# LIRADS 5

- DEFINITELY HCC
- 100% ACCURACY
- CRITERIA
  - NOT DEFINITE BENIGN ENTITY, NOT PROBABLE BENIGN ENTITY, NOT NON HCC MALIGNANCY
  - $\geq$  MASS WITH ARTERIAL PHASE HYPERENHANCEMENT AND  $\geq 1$  OF THE FOLLOWING : WASHOUT, CAPSULE, GROWTH

# 45 year old male

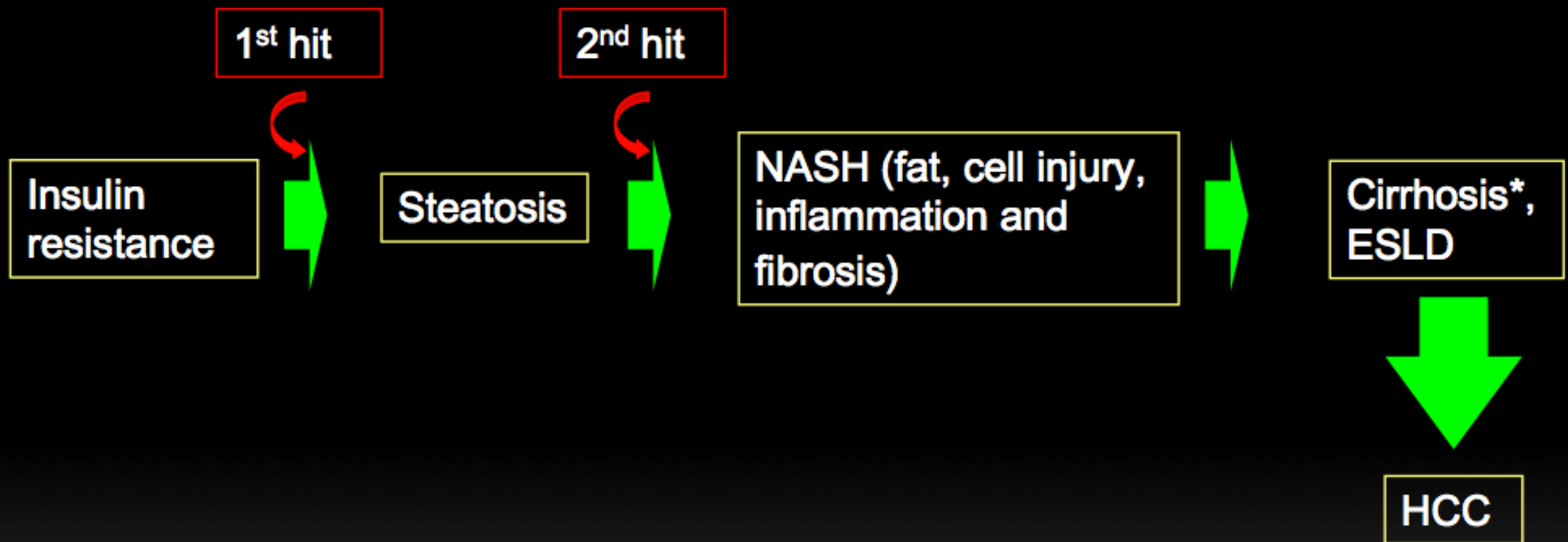
- No significant alcohol intake
- Fasting lipids
  - Mild to moderately elevated
- Type II DM
- AST 70
- ALT 95
- Negative viral hepatitis panel



# Why is the diagnosis of fatty liver disease important?

- Alcoholic vs. Nonalcoholic liver disease (NAFLD)
  - NAFLD-----NASH
  - Dramatic increase in prevalence in the West
    - 20 to 30% (estimates vary) people in the US
    - 10% children

# NAFLD (non alcoholic fatty liver disease)



\*6.4 million US adults have NAFLD and 640,000 of these may have cirrhosis (extrapolation from NHANES III data) (*Clarke, JAMA 2003*)

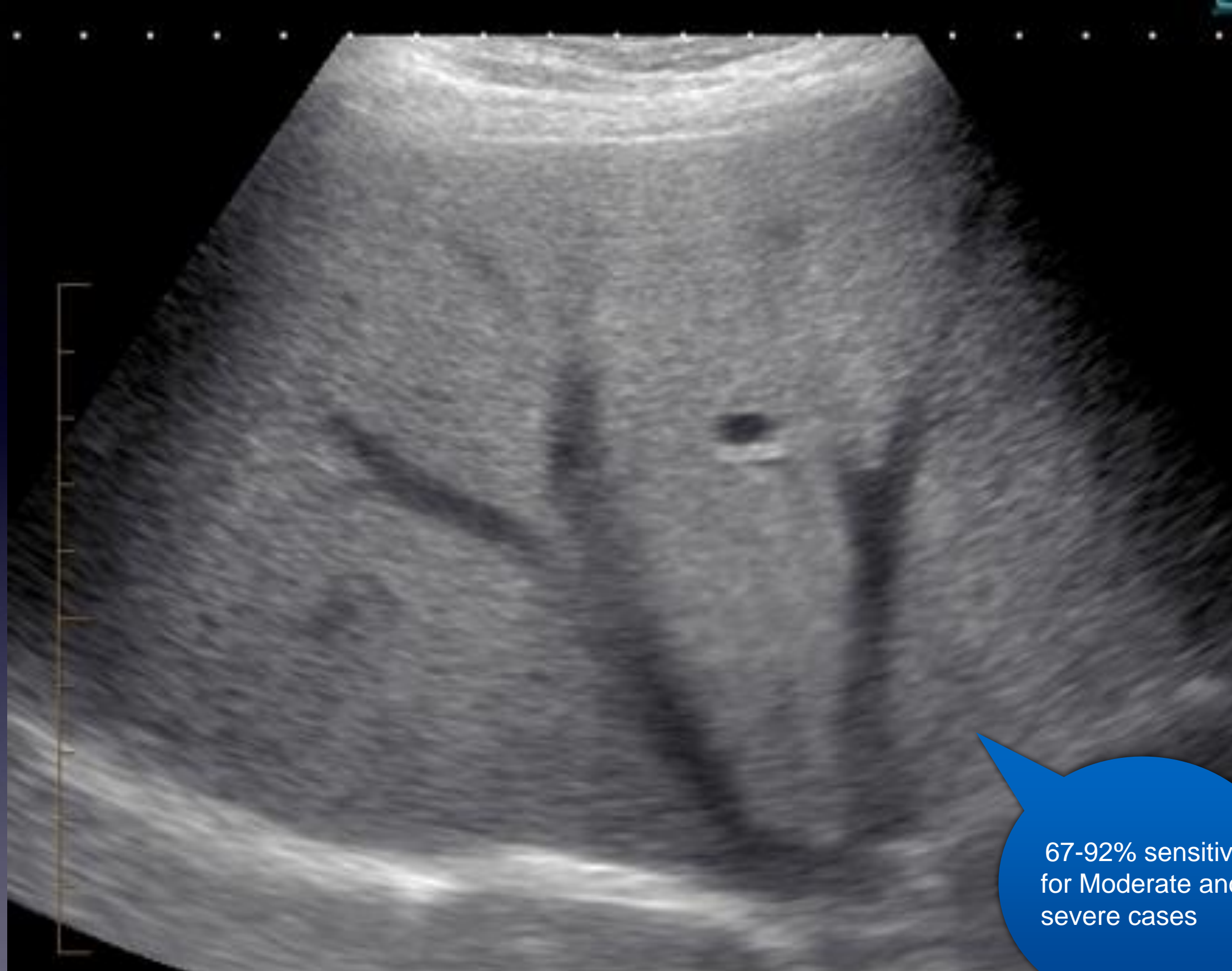# NAFLD/NASH---Cirrhosis

- 25% of patients with NAFL progress to NASH
- NASH is expected overtake chronic HCV infection for Transplantation in the US



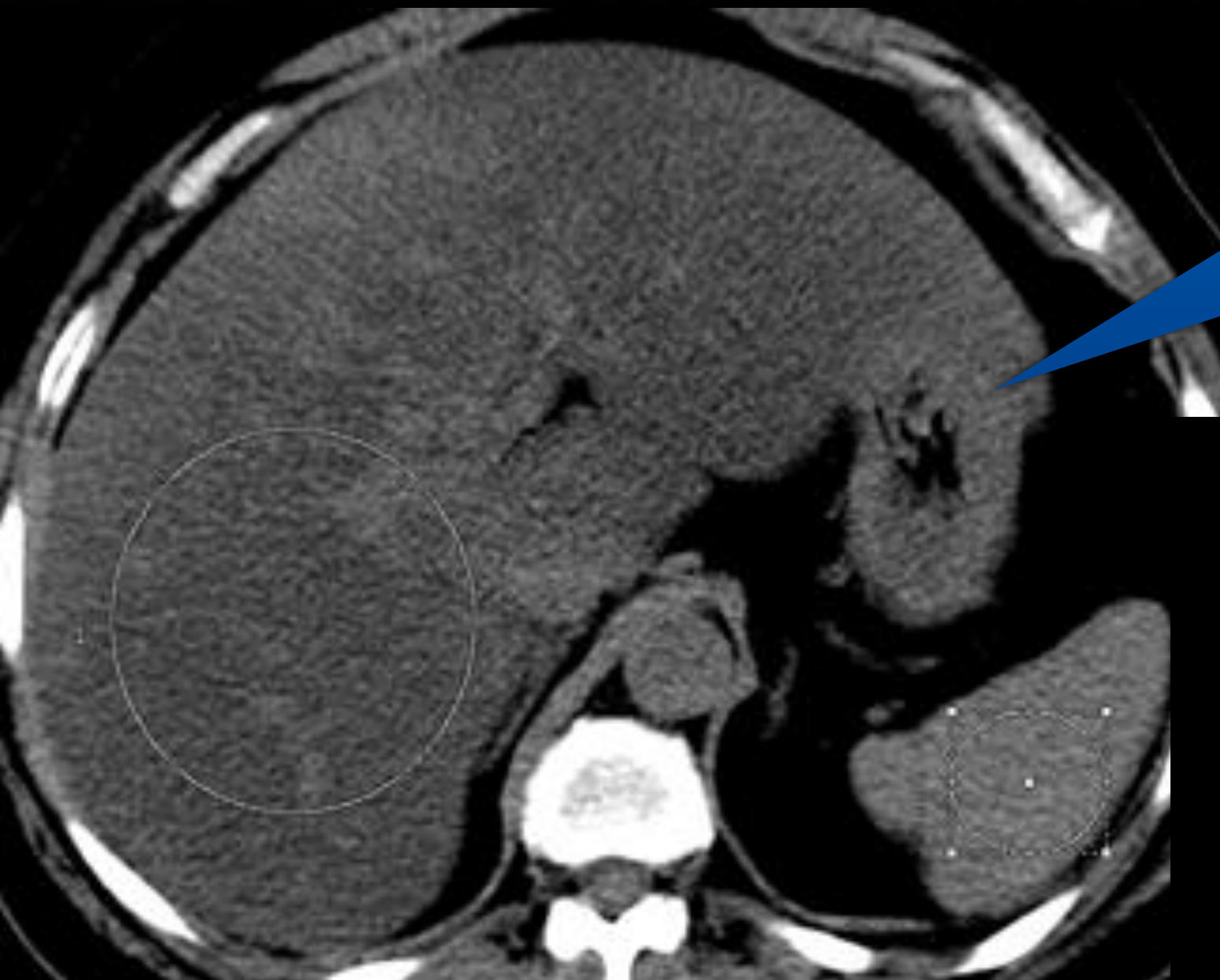
# Ultrasound Limitations

- Patient body habitus
- Overlap in imaging appearance with fibrosis
- Subjective (tech and doctor)

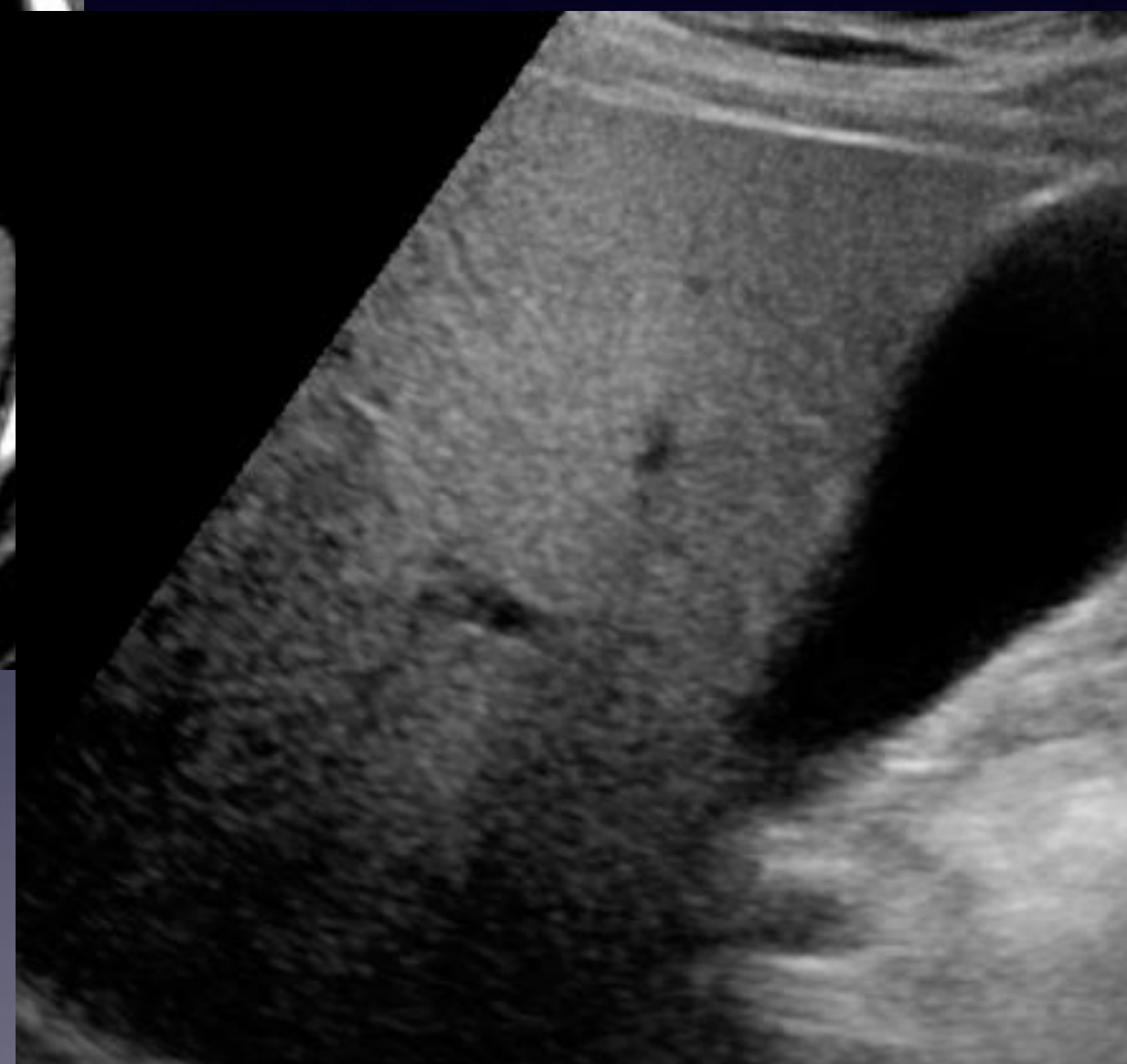

Trans Liver Rt \_

67-92% sensitive  
for Moderate and  
severe cases

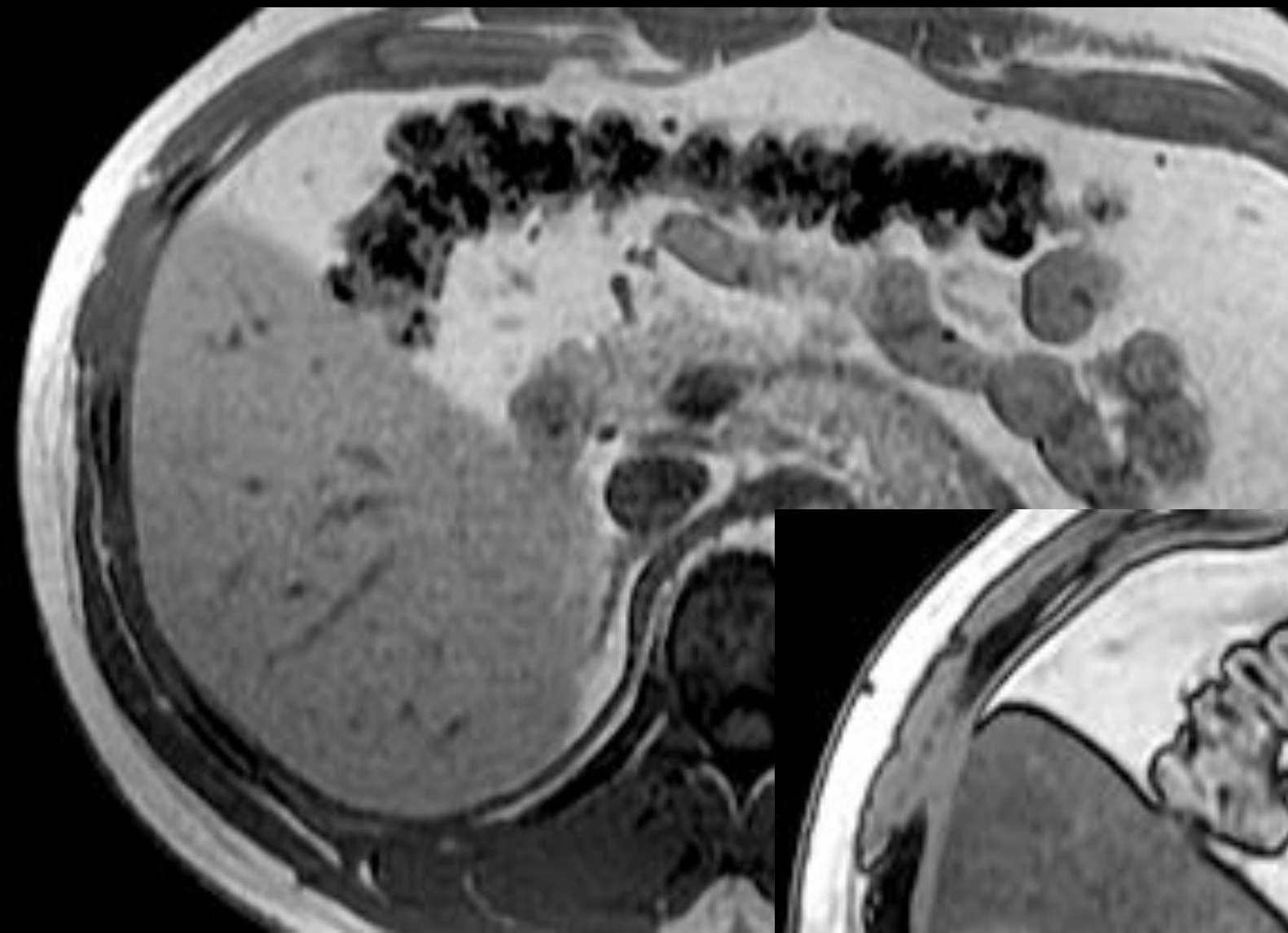


30% liver fat content correlates to an attenuation of 40 H on unenhanced CT scans

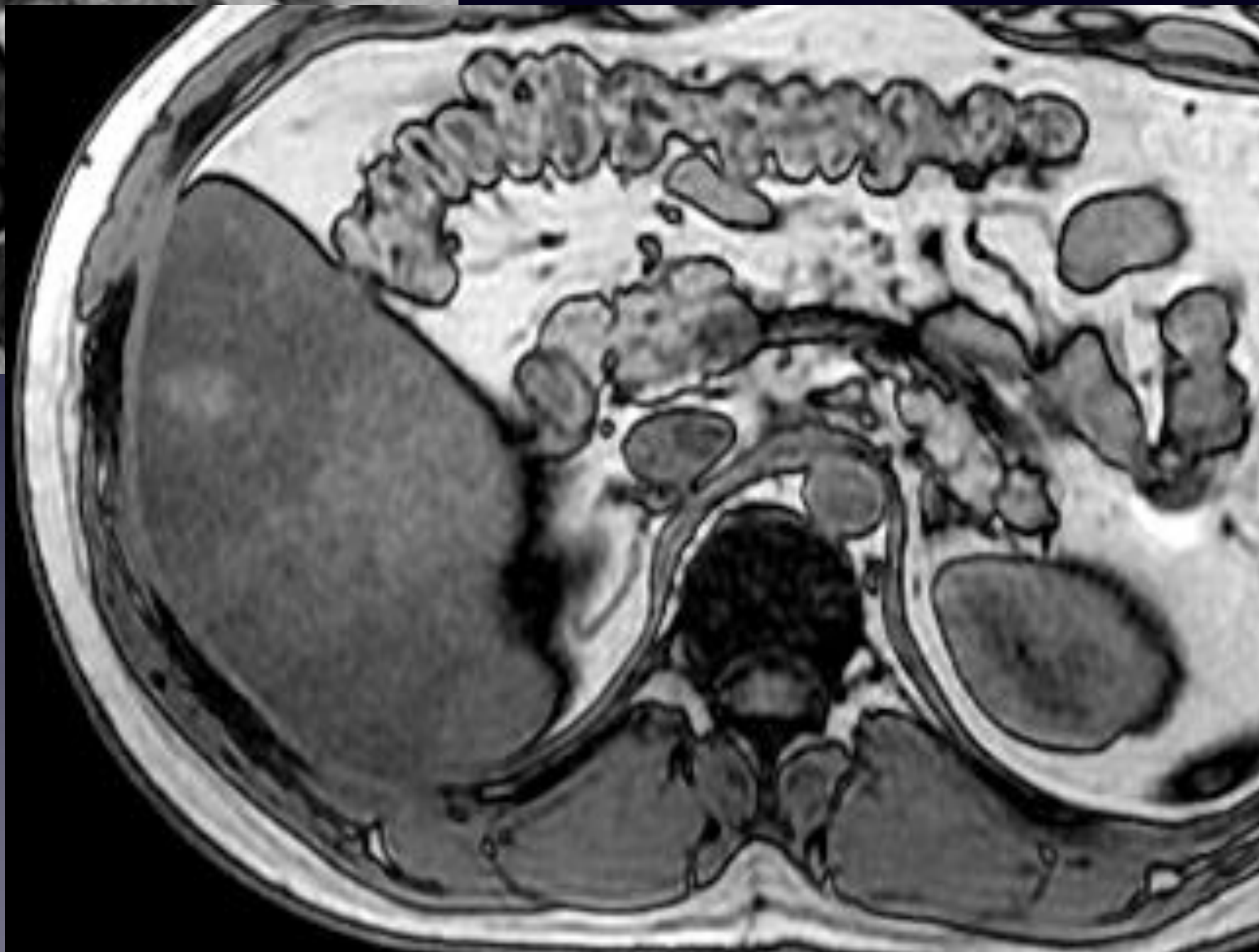


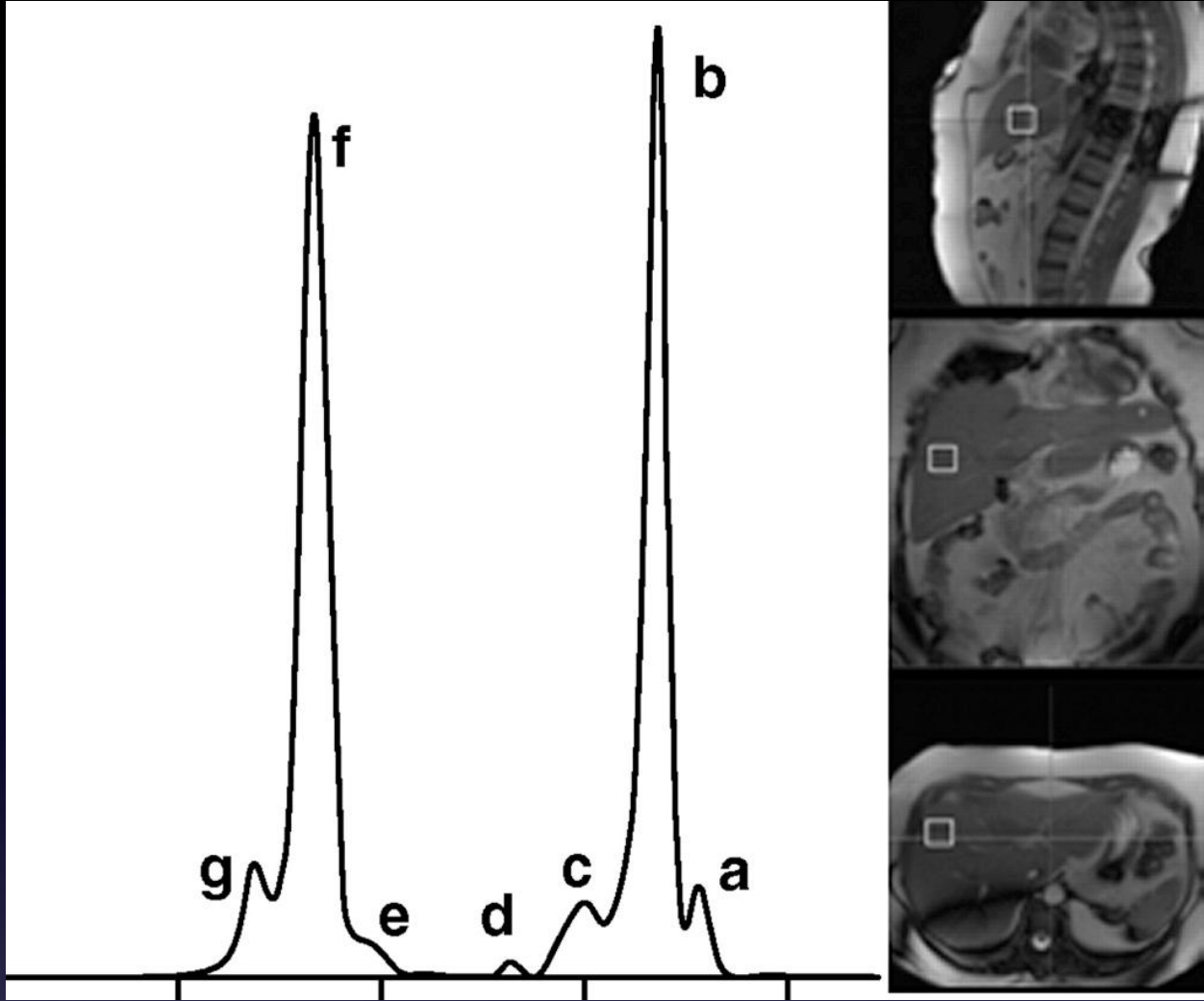
It has been suggested that persons with a hepatic fat content greater than 30% should not be liver donors.





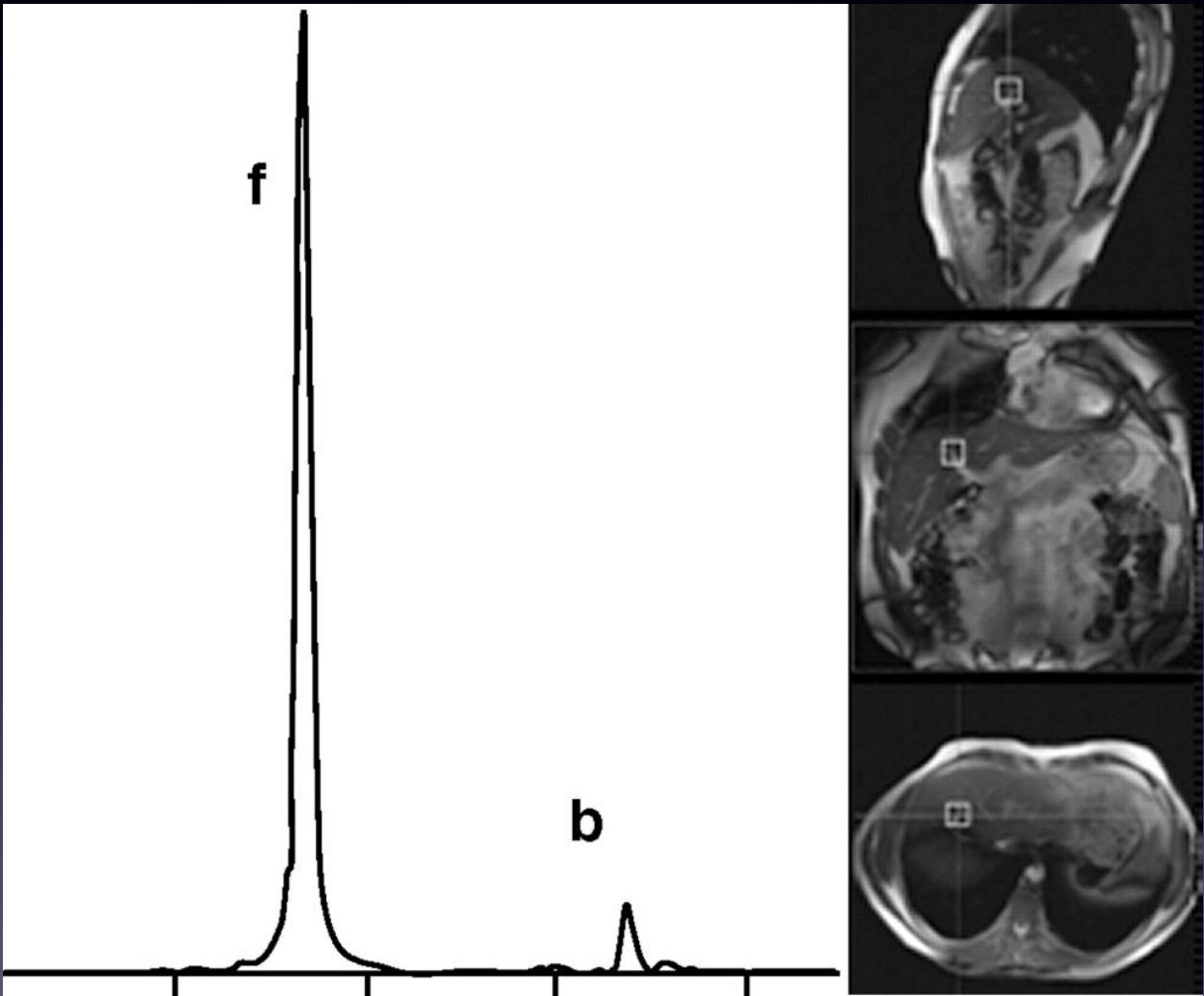
Chemical shift imaging has been shown to be useful in assessing reduction in fatty liver after insulin sensitizing therapy





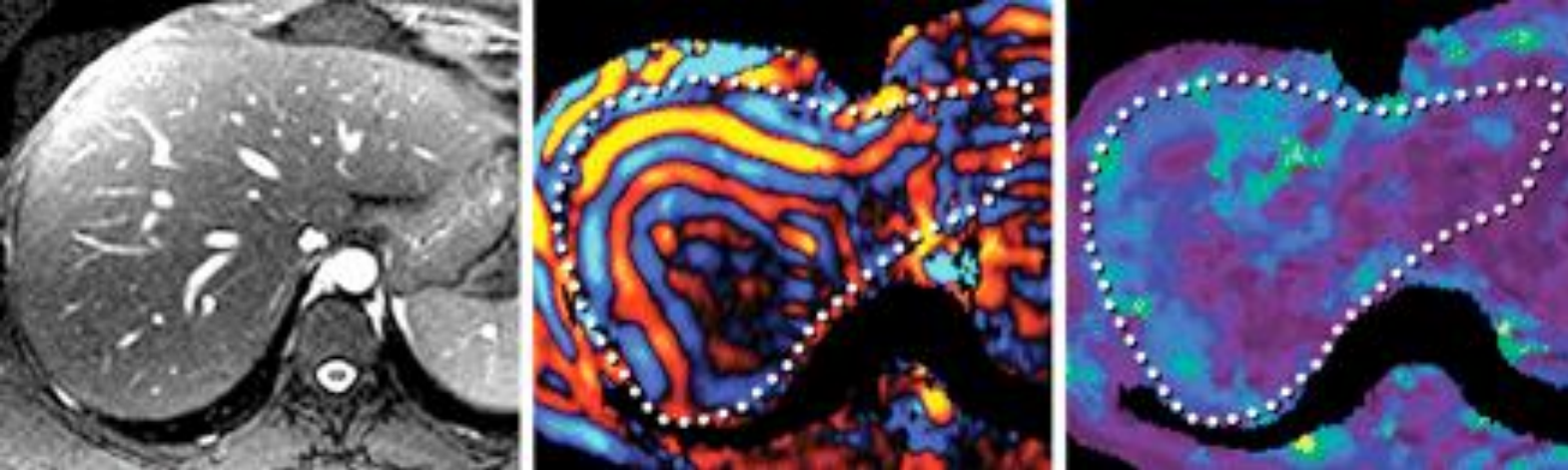
**Fig. 4** —Proton (<sup>1</sup>H) hepatic MR spectroscopy. Single-voxel spectrum in 39-year-old-woman with hepatic steatosis

Normal liver contains less than 5% fat by weight. In patient with hepatic steatosis, amplitude of methylene resonance (b) is much higher.

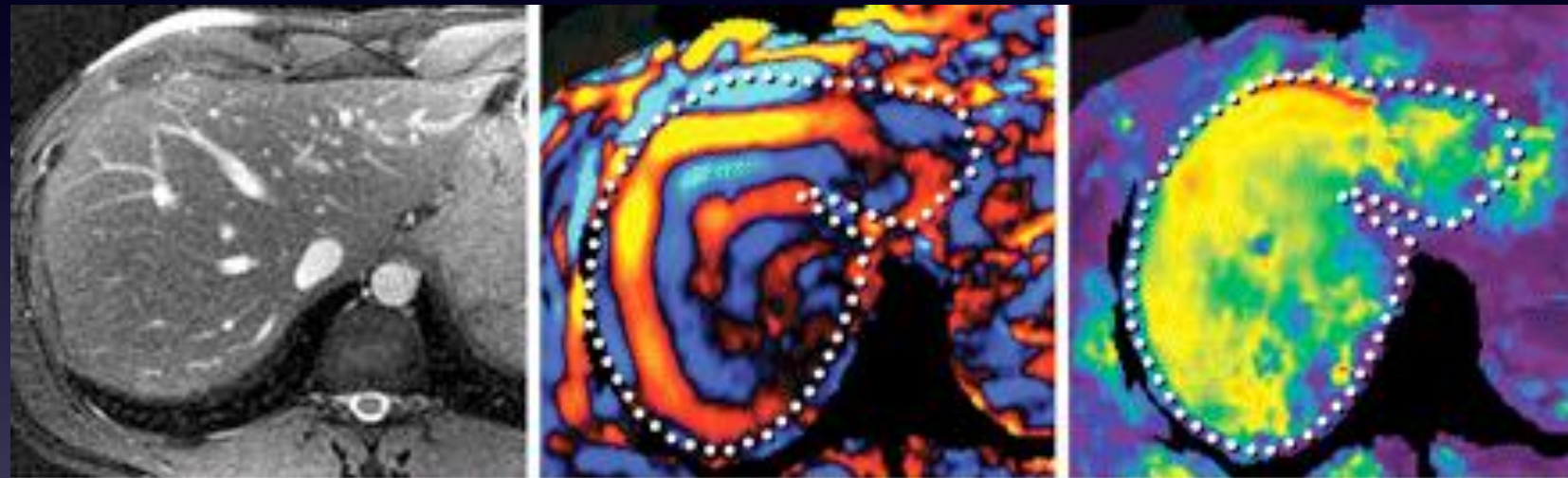


**Fig. 5** 29-year-old asymptomatic male volunteer (B). In healthy volunteer



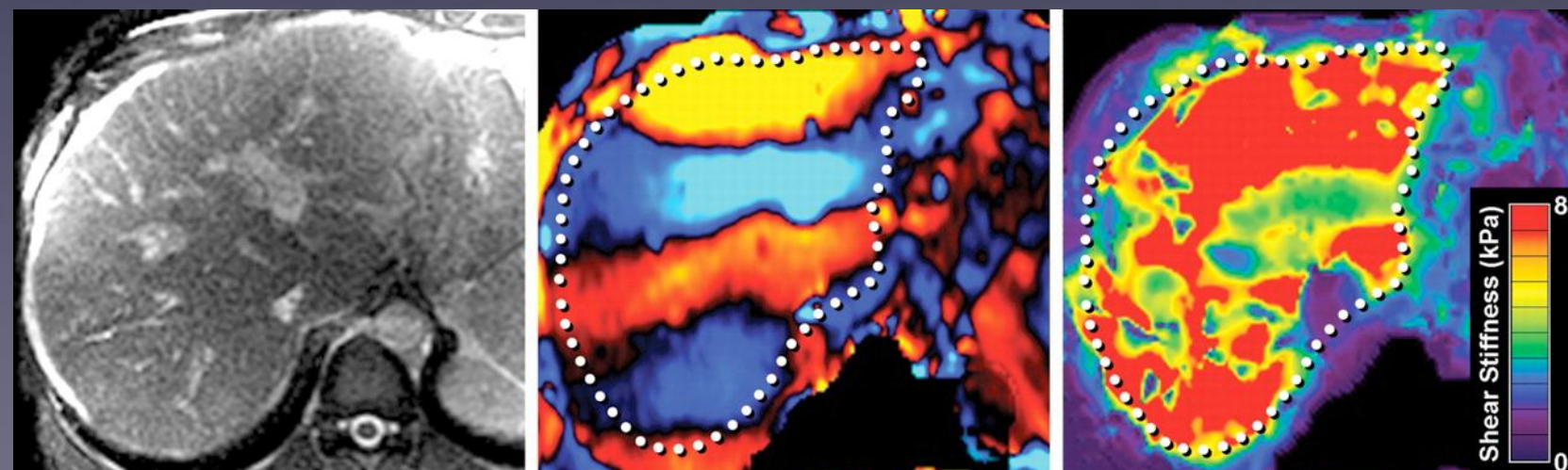


**Fig. 5A** —Assessment of hepatic fibrosis with MR elastography (MRE) in three patients with chronic **liver** disease: T2-weighted anatomic images (*top*), MRE wave images (*middle*), and MR elastograms showing stiffness of **liver** tissue (*bottom*). In 36-year-old man with **liver steatosis** and no fibrosis, **liver** has normal appearance in anatomic image, and wave image shows that shear waves at 60 Hz have short wavelength, consistent with normally soft mechanical characteristics of normal **liver** tissue. Elastogram shows mean stiffness value of 2.1 kPa, well below upper limit of normal (2.9 kPa), indicating absence of hepatic fibrosis.



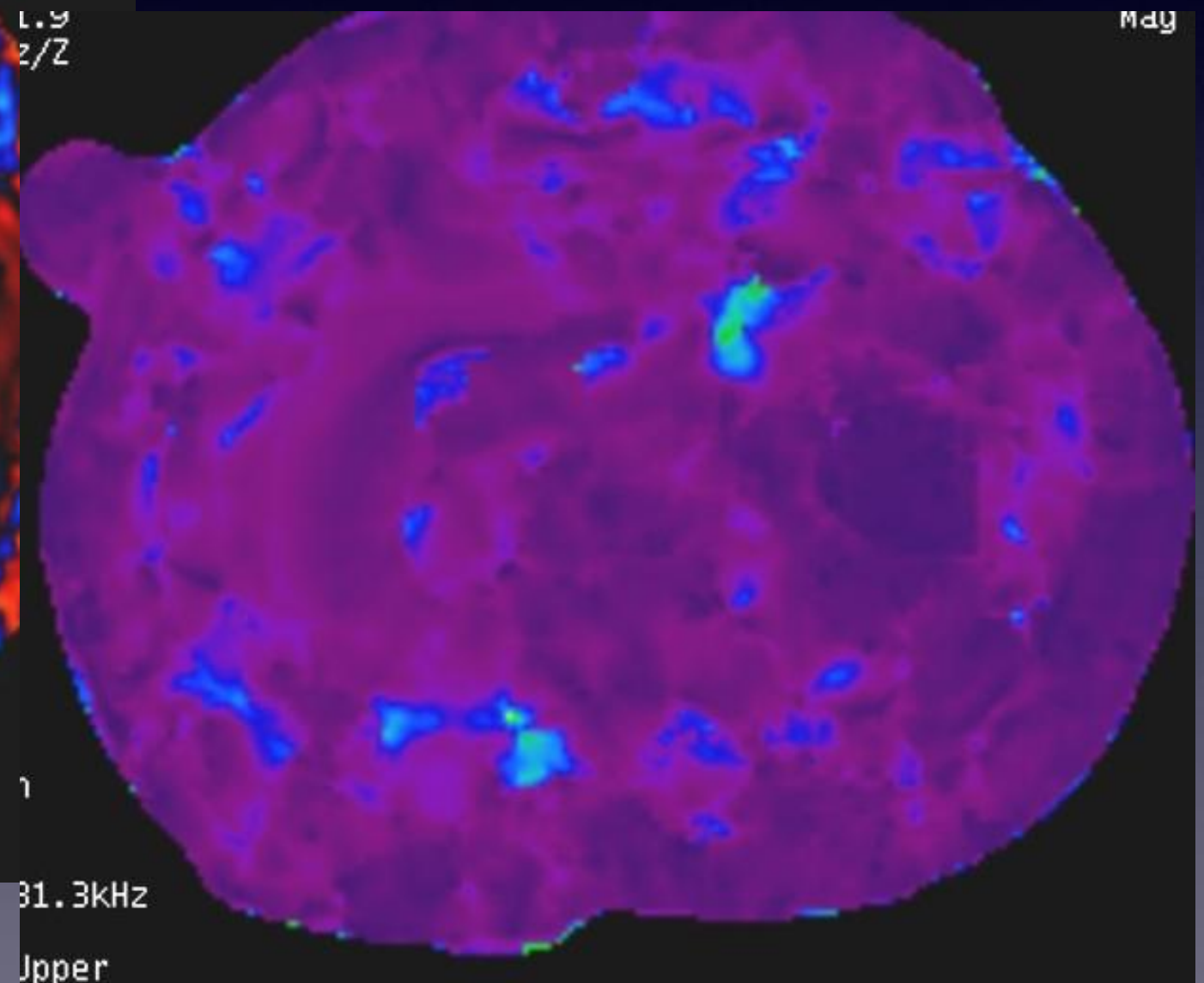
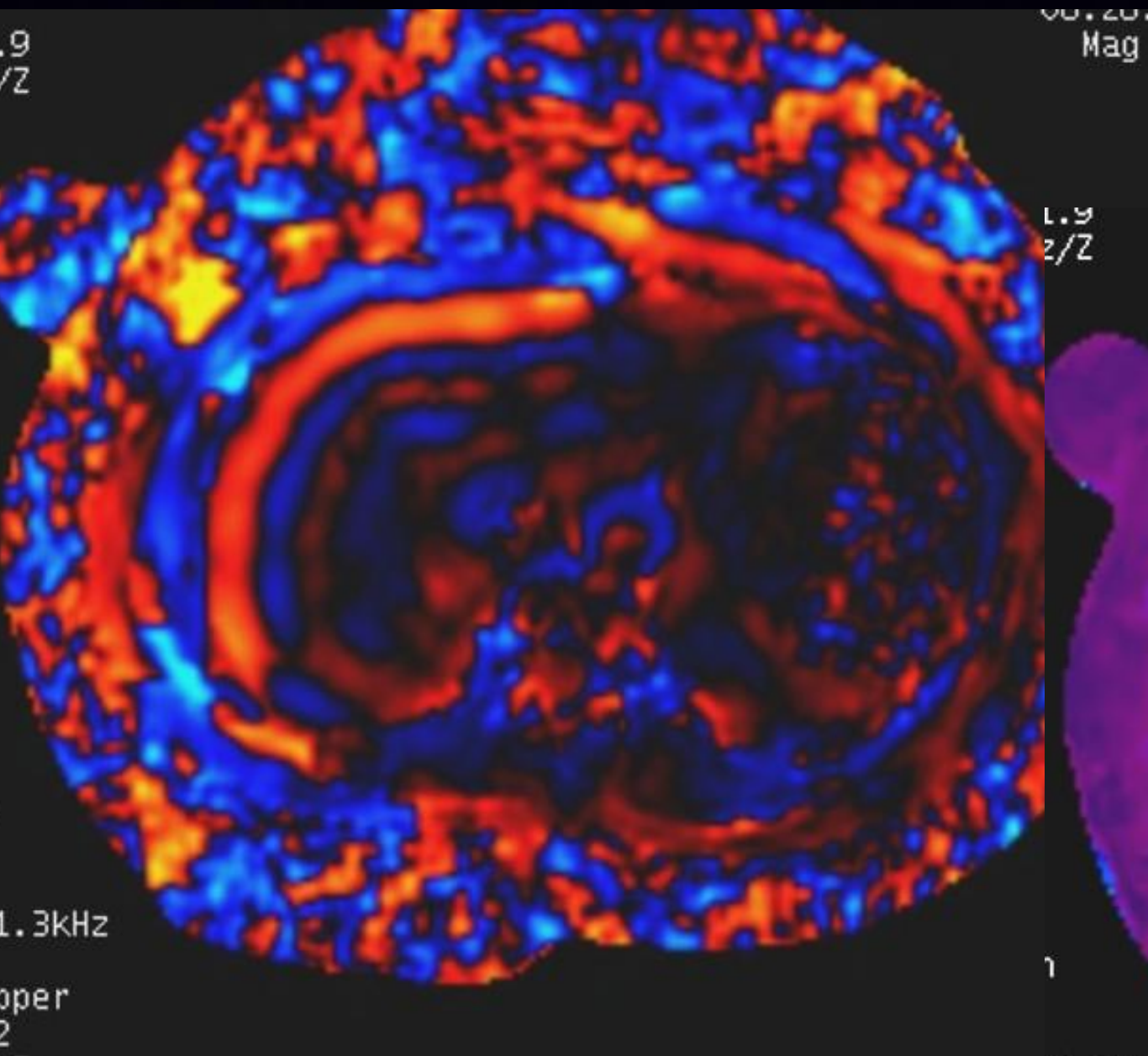
**Fig. 5B** —Assessment of hepatic fibrosis with MR elastography (MRE) in three patients with chronic **liver** disease: T2-weighted anatomic images (*top*), MRE wave images (*middle*), and MR elastograms showing stiffness of **liver** tissue (*bottom*). 29-year-old woman with hepatic **steatosis** and mild fibrosis also has normal-appearing **liver**, but wave images show relative prolongation of visualized shear waves. Elastogram shows abnormally high mean stiffness value of 4.8 kPa, consistent with moderate hepatic fibrosis. Biopsy showed stage 1 fibrosis.

**Fig. 5C** —Assessment of hepatic fibrosis with MR elastography (MRE) in three patients with chronic **liver** disease: T2-weighted anatomic images (*top*), MRE wave images (*middle*), and MR elastograms showing stiffness of **liver** tissue (*bottom*). 43-year-old man with primary sclerosing cholangitis has abnormal hepatic contour and ascites, consistent with chronic **liver** disease. Wave image shows marked lengthening of visualized shear waves. Elastogram shows that **liver** stiffness is markedly heterogeneous, with many confluent areas measuring more than 8 kPa in stiffness. Biopsy confirmed presence of moderate to advanced fibrosis.






# Normal Liver kPa <2.5

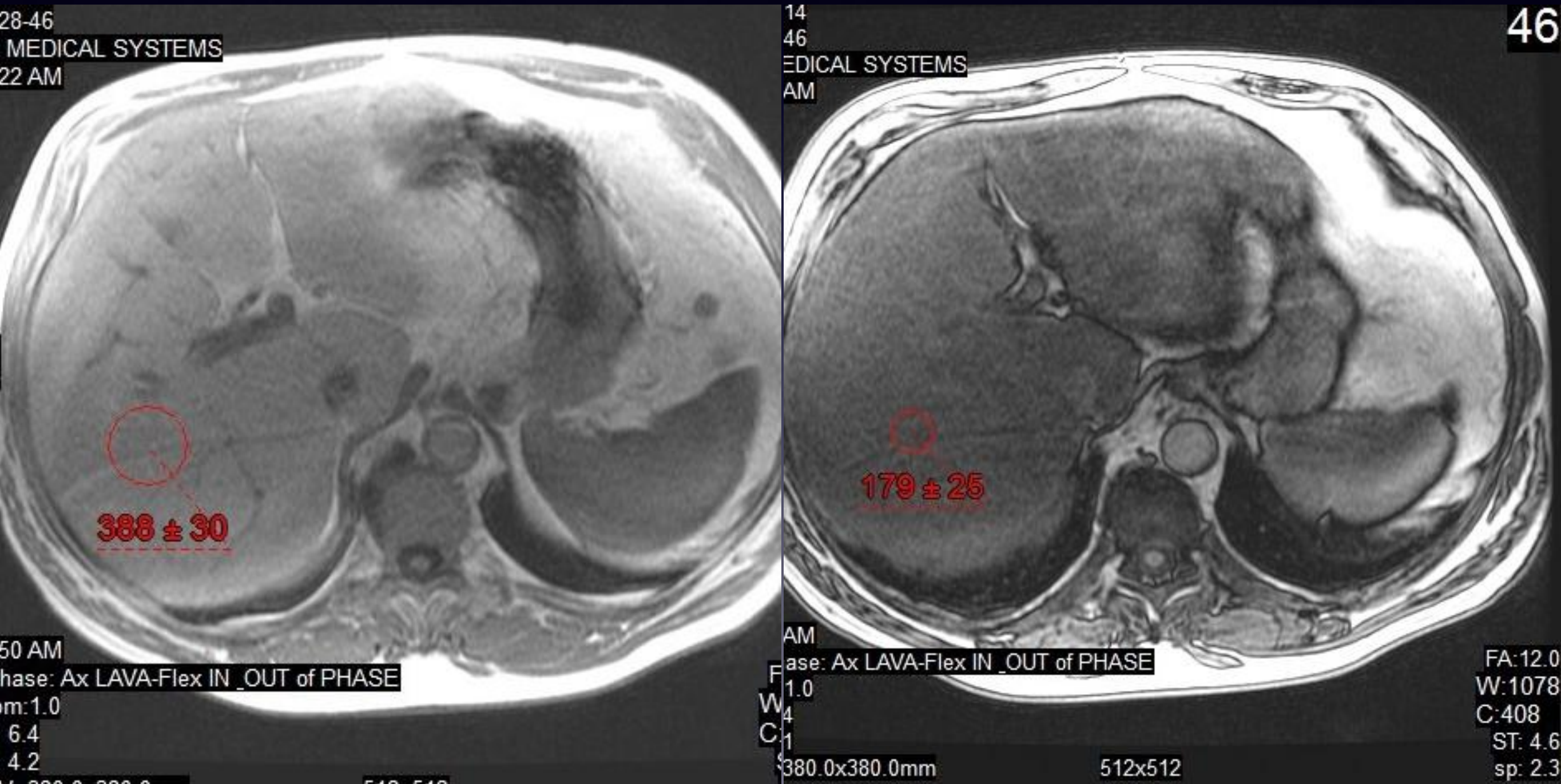


# Normal Liver kPa <2.5



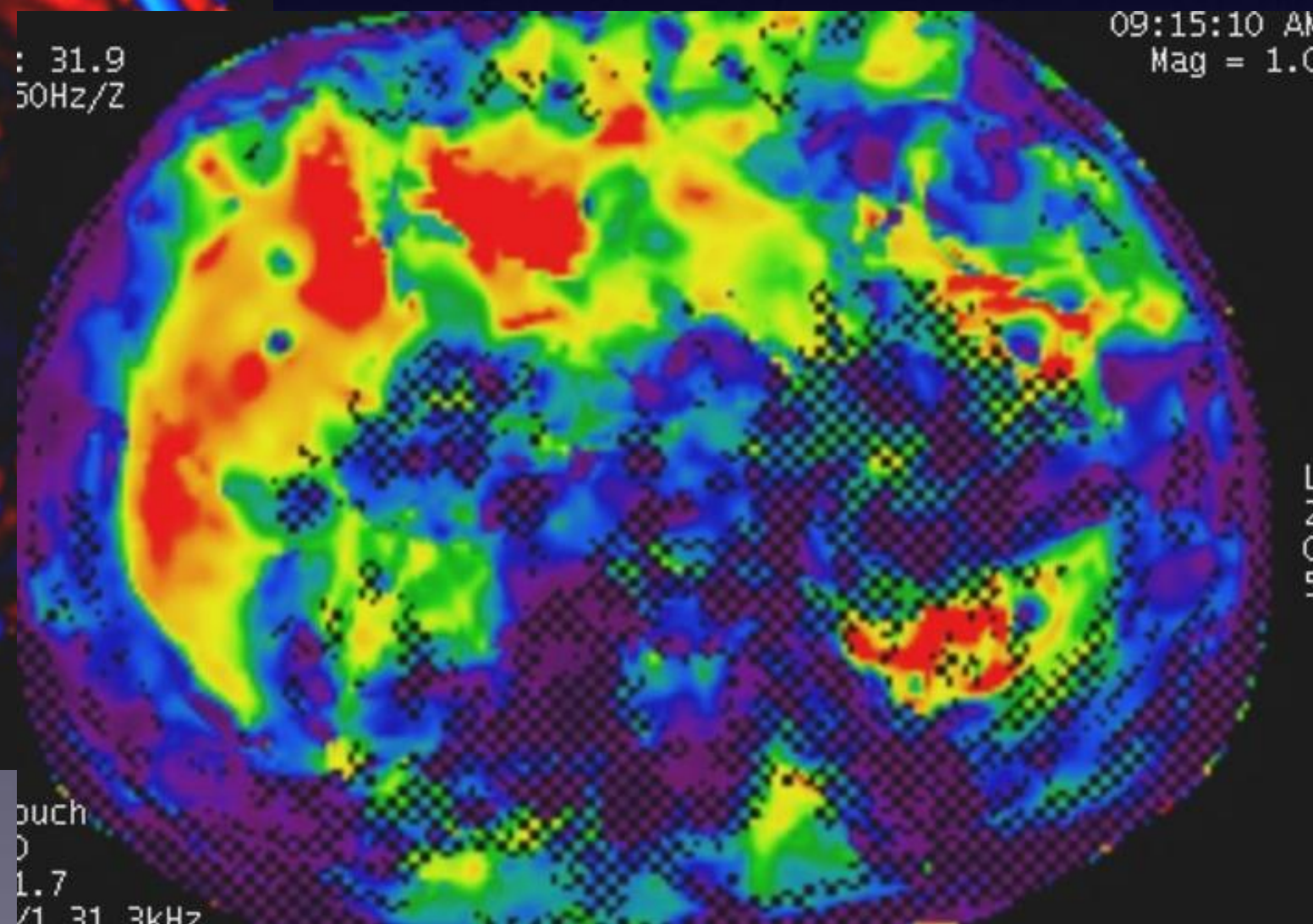
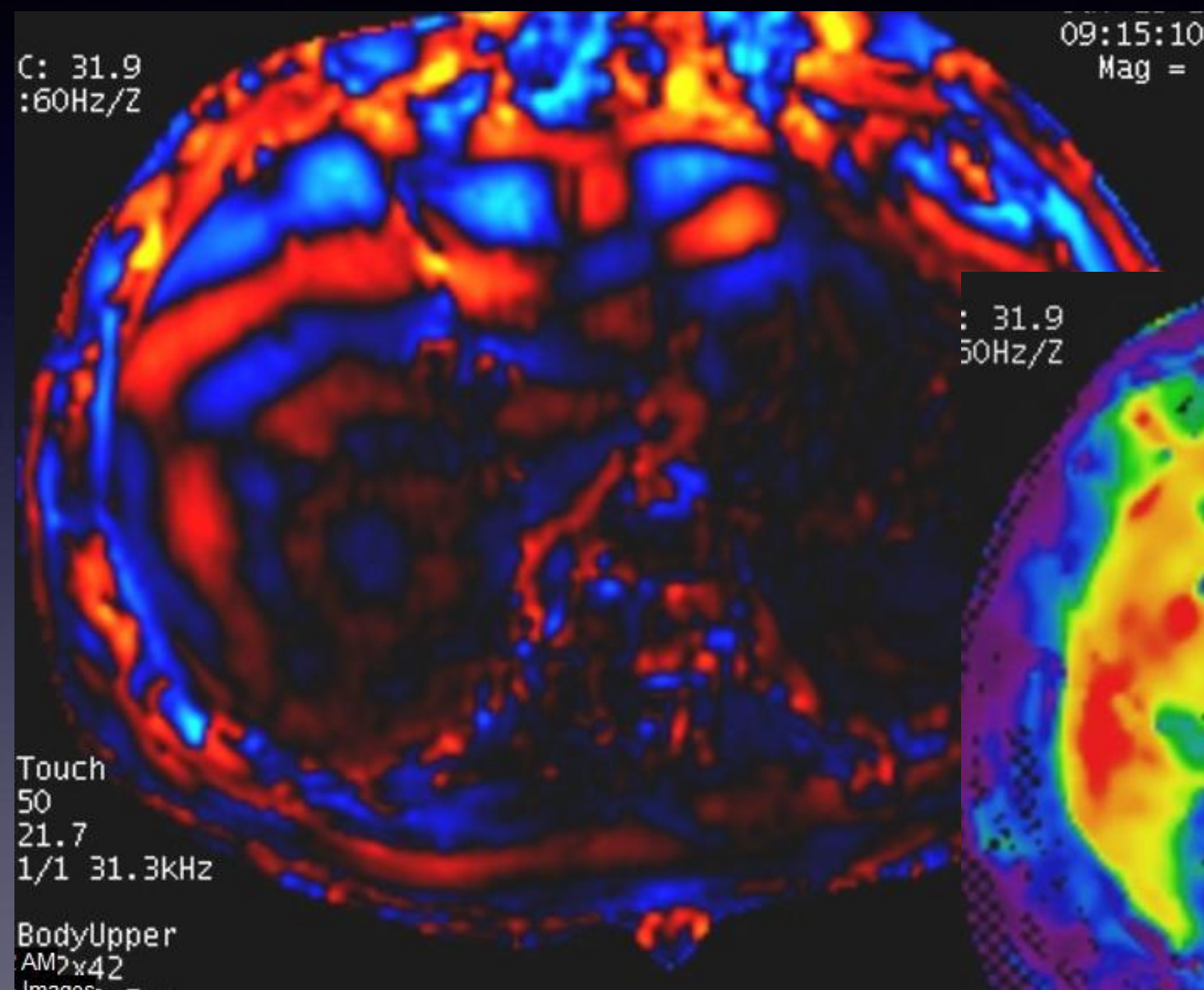


# Fatty Liver suspected NASH



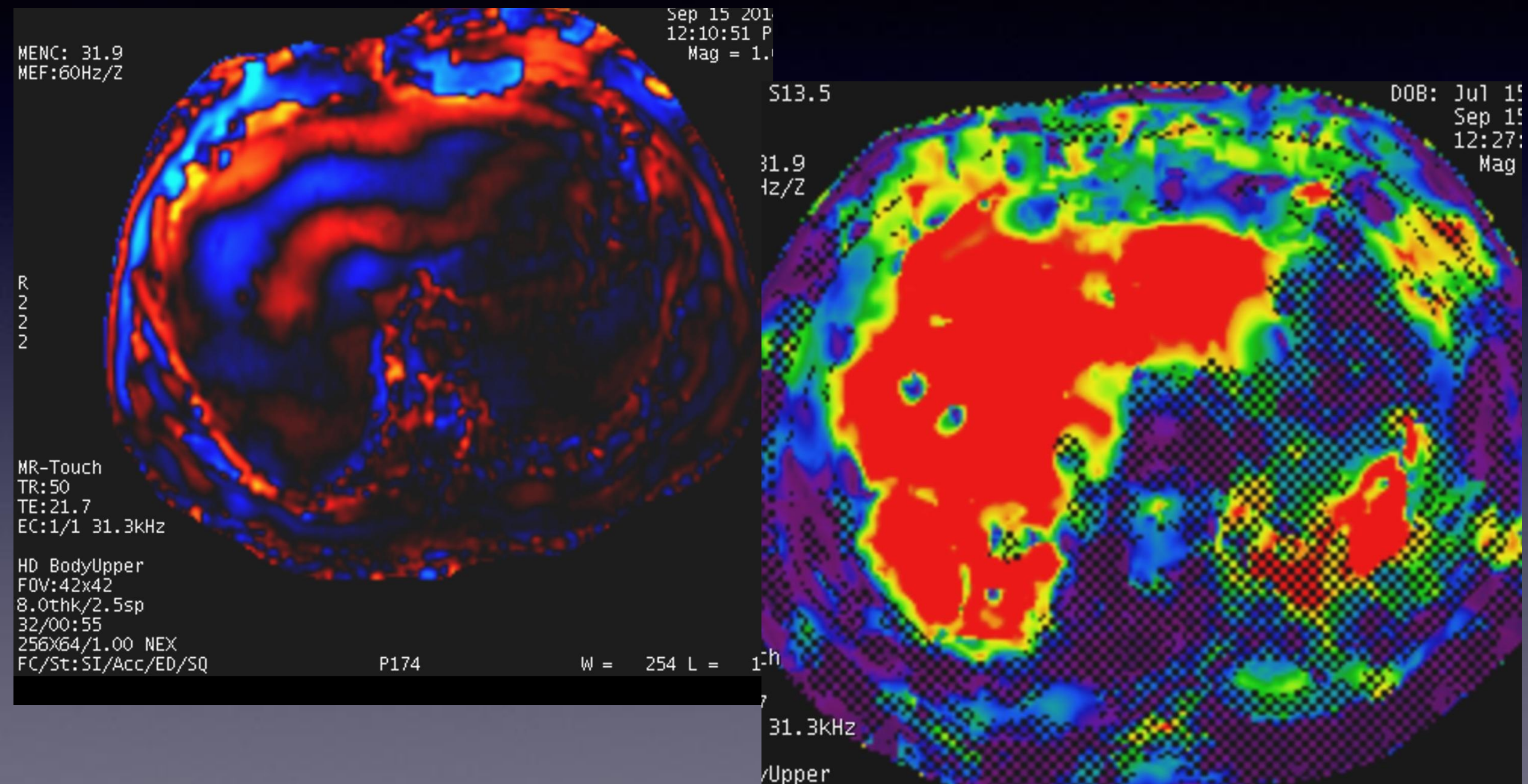


# NASH kPa 4.0-5.0 stage 3 to 4 fibrosis





# Cirrhosis $> 5.0$ kPa



Thank You